J. Parasitol., 88(3), 2002, pp. 634–637
© American Society of Parasitologists 2002

Intestinal Coccidiosis in a Spinner Dolphin (*Stenella longirostris*)

J. P. Dubey, J. S. Eggers*, and T. P. Lipscomb*, United States Department of Agriculture, Agricultural Research Service, Animal and Natural Resources Institute, Parasite Biology, Epidemiology and Systematics Laboratory, Beltsville Agricultural Research Center, Building 1001, Beltsville, Maryland 20705-2350; and *Department of Veterinary Pathology, Armed Forces Institute of Pathology, Washington, D.C. 20306-6000. *e-mail: jdubey@anri.barc.usda.gov*

ABSTRACT: Intestinal coccidiosis was diagnosed histologically in the small intestine of a spinner dolphin (*Stenella longirostris*). Numerous intralesional coccidia were present in mucosal epithelial cells. Schizonts, gamonts, and unsporulated oocysts were seen. Schizonts were up to 30 × 20 μm and contained up to 16 merozoites, which measured 10–12 × 2 μm. Unsporulated oocysts were about 9–12 × 8–10 μm. This is the first report of intestinal coccidiosis in a spinner dolphin.

Coccidial organisms of the Eimeriidae are not commonly reported to infect marine mammals. The first case of intestinal coccidiosis in a spinner dolphin (*Stenella longirostris*) is presented in this article.

A neonatal spinner dolphin was found washed up on the Wainae Coast of Hawaii. A complete set of tissues was collected at necropsy and fixed in 10% buffered neutral formalin. Paraffin-embedded, 5-μm sections were cut and stained with hematoxylin and eosin for microscopic examination. Transmission electron microscopy was performed on formalin-fixed sections of small intestine retrospectively.

Gross necropsy examination revealed a very young dolphin with no evidence of antemortem trauma. The stomach was small, and there was no evidence in the gastrointestinal tract of the animal having nursed recently. The lungs floated when placed in formalin, suggesting that the animal had not been stillborn.

Main histologic findings were limited to the small intestine and lungs. There was a mild subacute interstitial pneumonia, with low numbers of inflammatory cells present multifocally in alveoli, the cause of which was not apparent. Within the epithelial cells lining the villi of the small intestine, there were numerous protozoans associated with epithelial necrosis and mild to moderately increased numbers of lymphocytes, plasma cells, and eosinophils. Lymphoid hyperplasia was present multifocally within lymph nodes compatible with a normal response to antigenic stimulation. Moderate congestion was observed in multiple tissues and was most likely a nonspecific terminal change.

Protozoans were located in intestinal epithelial cells lining the villus and the glands of Lieberkühn (Fig. 1). Most parasites were located

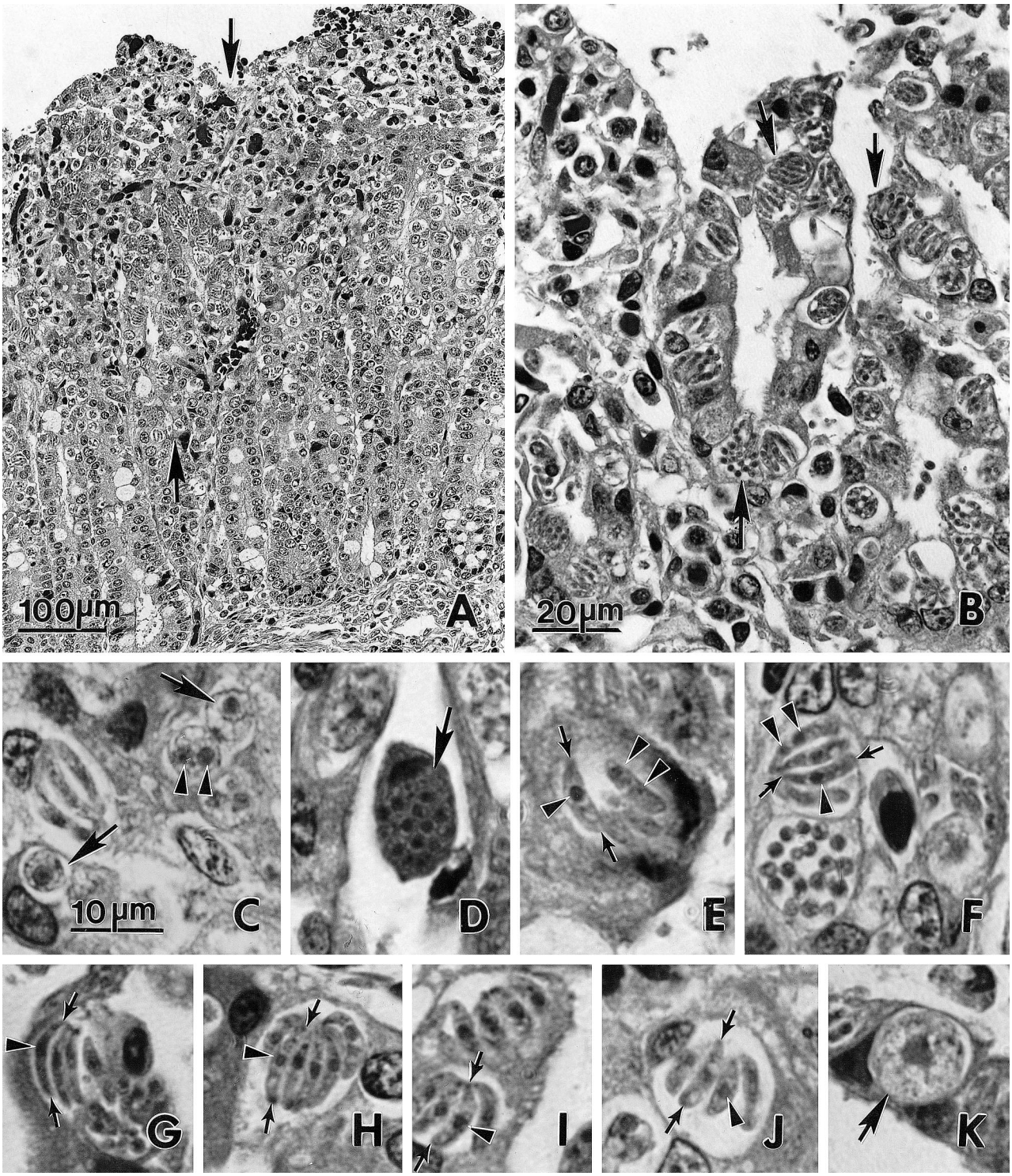

FIGURE 1. Lesions and coccidia in small intestine of the dolphin. Hemotoxylin and eosin stain. Bar in C–K is 10 µm. (**A**) Desquamation of epithelium and villar contents and parasitization by coccidia in upper half (arrows) of the mucosa. (**B**) Coccidia (arrows) in epithelial cells of glands of Lieberkühn. (**C**) Two uninucleate (arrows) schizonts or gamonts and a binucleate (arrowheads) meront. (**D**) Multinucleate schizont. (**E–J**) Schizonts with longitudinally cut merozoites (arrows). Note the structure and position of nucleus (arrowheads) in merozoites. (**K**) Macrogamont.

toward the distal two-thirds of the villus (Fig. 1A). In some villi, nearly all epithelial cells were parasitized. Schizonts, female gamonts, and oocysts were the only stages seen. Uninucleate to multinucleate schizonts were present (Fig. 1C, D). Schizonts were up to 30 × 20 µm, but most were 15 × 10 µm and contained up to 16 merozoites. Merozoites differed in size and shape (Fig. 1). It could not be ascertained if there was more than 1 structurally distinct merozoite. Some merozoites appeared to have 2 nuclei (Fig. 1E, F) and were more slender than others (Fig. 1E–J). Longitudinally cut merozoites were approximately 10–15 × 2–3 µm (n = 10). Oocysts and mature female gamonts were identified by

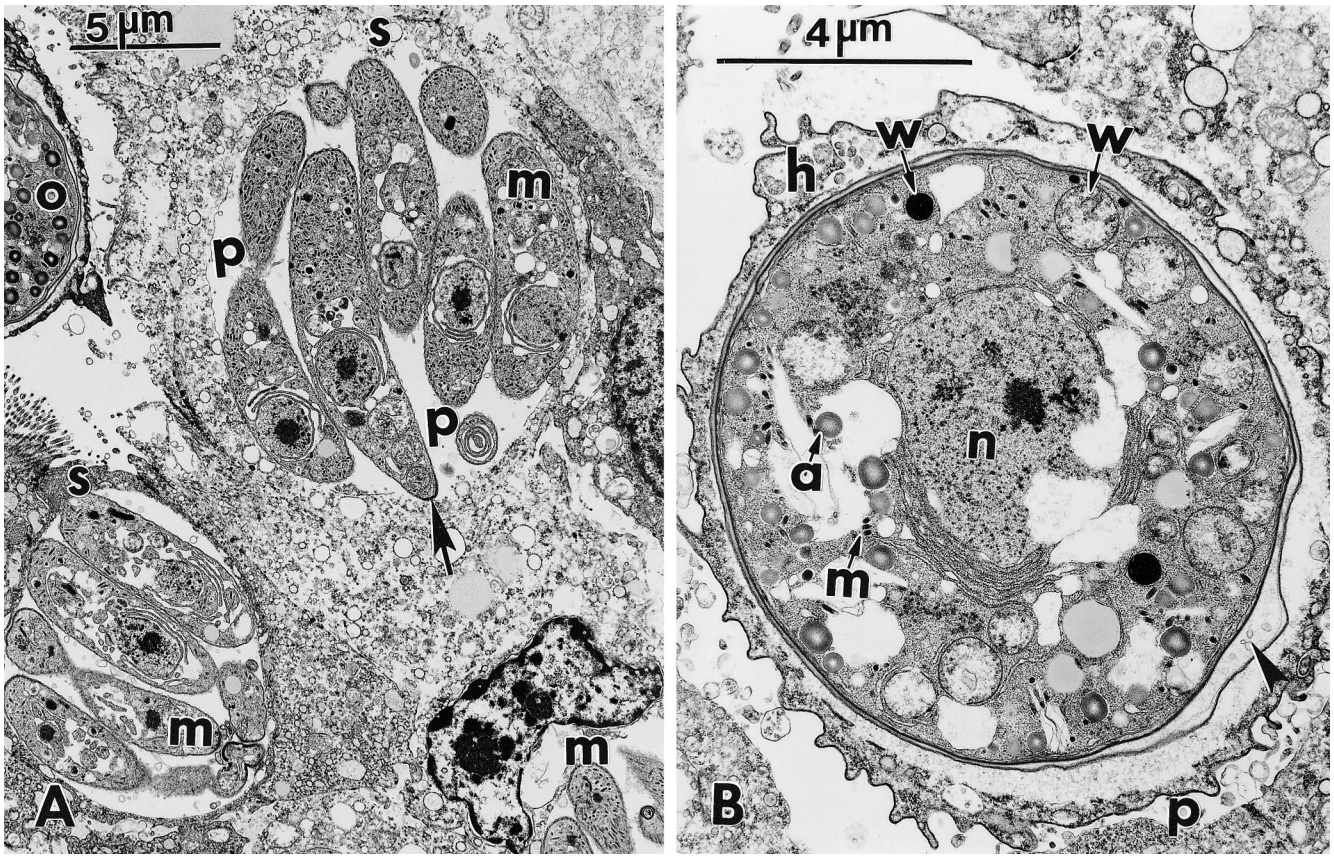

FIGURE 2. Transmission electron micrographs of schizonts (s) and oocysts (o) in the intestine of the dolphin. (**A**) Two schizonts (s) with fully formed merozoites (m) located in parasitophorous vacuoles (p). Arrow points to a longitudinally cut merozoite. (**B**) Oocyst located in a parasitophorous vacuole (p) of the host cell (h) cytoplasm. This macrogamont is in early stages of oocyst formation and contains wall-forming bodies (w), micronemes (m), amylopectin (a), and a centrally placed nucleus (n). Secretions are present (arrowhead) in between 2 oocyst walls.

the presence of a large central nucleus (Fig. 1K). Oocysts were unsporulated and were approximately 10 µm in diameter (Fig. 1K).

Ultrastructurally, only schizonts and oocysts were visualized, and they were located in parasitophorous vacuoles in the cytoplasm of epithelial cells (Figs. 2, 3). Merozoites in some schizonts were still attached to each other by their posterior (nonconoidal) ends. Although protozoans were autolyzed, some organelles were recognized. Merozoites contained a conoid, pellicular tubules, at least 2 rhoptries with anterior narrow and a posterior bulbous end located anterior to the nucleus (Fig. 3). There were numerous micronemes that were haphazardly arranged (Fig. 3A, B). Although micronemes were concentrated toward the conoidal end, few were located almost to the nonconoidal end (Fig. 3). Oocysts were unsporulated.

The cause of death in this neonate was most likely debilitation associated with a lack of food intake (noted at necropsy), marked coccidial enteritis, and mild pneumonia. The exact age of the dolphin was unknown; therefore, it is uncertain if the infection was congenital.

Structurally, the protozoan in the dolphin is a coccidian. *Eimeria* and *Isospora* are the 2 important coccidian genera with a direct fecal–oral cycle. Coccidial infections caused by *Isospora* (*Cystoisospora*) *israeli* in a fur seal (Kuttin and Kaller, 1992), *Isospora delphini* in a bottle nosed dolphin (*Tursiops truncatus*) (Kuttin and Kaller, 1996), and *Eimeria phocae* in harbor seals (*Phoca vitulina*) and African fur seal (*Acrtocephalus pusillus*) (Hsu et al., 1974) were reported. The coccidian present in the dolphin in the present report was not identified because sporulated oocysts were not available for examination.

The authors would like to thank John Jenkins for the excellent electron micrographs.

LITERATURE CITED

HSU, C. K., E. C. MELBY, AND N. H. ALTMAN. 1974. *Eimeria phocae* sp. n. from the harbor seal (*Phoca vitulina concolor*). Journal of Parasitology **60:** 399–402.

KUTTIN, E. S., AND A. KALLER. 1992. *Cystoisospora israeli* n. sp. causing enteritis in a South African fur seal. Aquatic Mammals **18:** 79–81.

———, AND ———. 1996. *Cystoisospora delphini* n. sp. causing enteritis in a bottle-nosed dolphin (*Tursiops truncatus*). Aquatic Mammals **22:** 57–60.

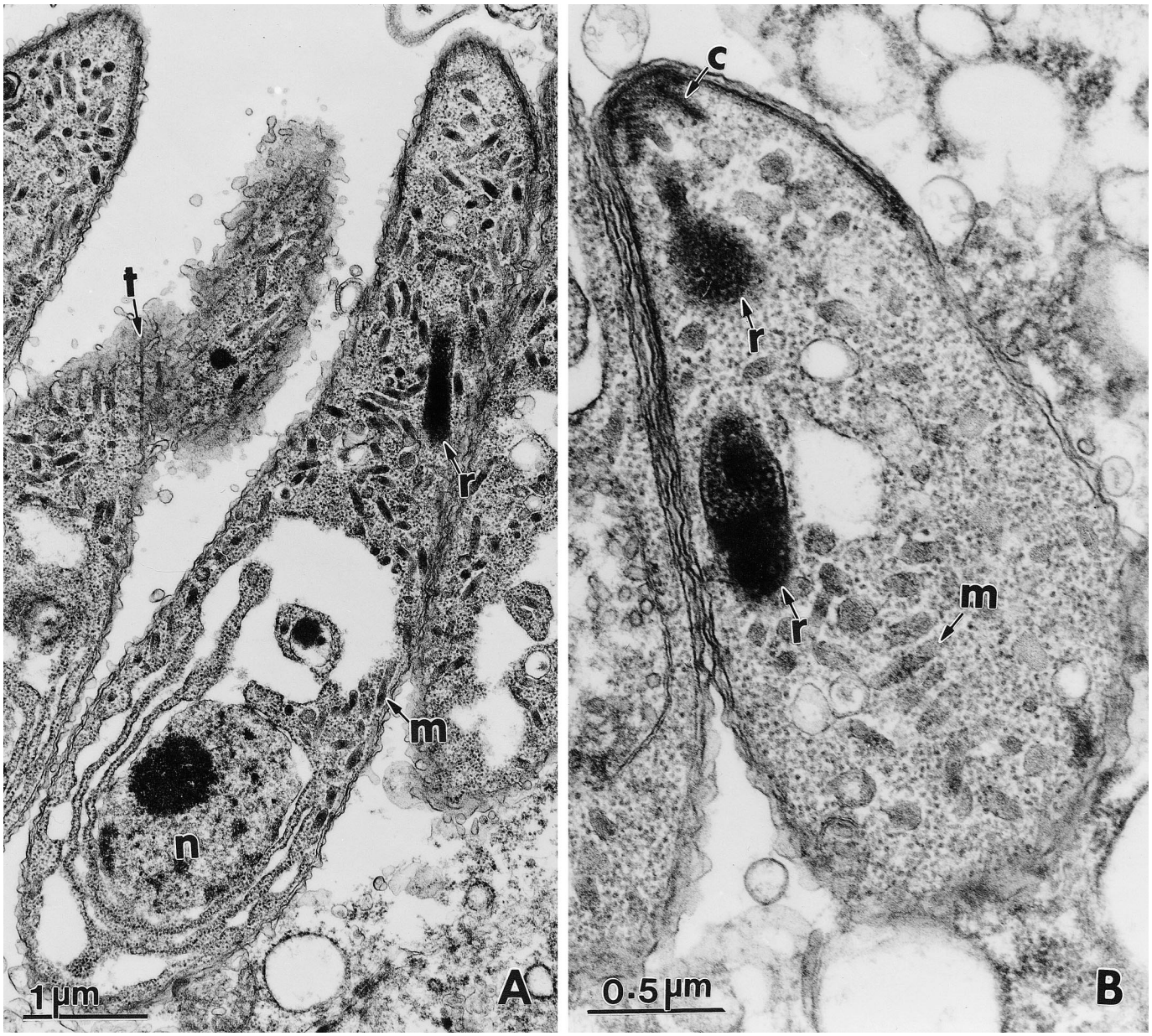

FIGURE 3. Transmission electron micrographs of 2 merozoites in the intestine of the dolphin. (**A**) Longitudinally cut merozoite. (**B**) Conoidal end of a merozoite. Note: conoid (c), micronemes (m), rhoptries (r), pellicular microtubules (t), and nucleus (n) in merozoites.