Available online at www.sciencedirect.com
SCIENCE DIRECT®
ELSEVIER
International Journal for Parasitology 33 (2003) 1437–1453
The Australian Society for Parasitology Inc.
INTERNATIONAL Journal for PARASITOLOGY
www.parasitology-online.com

Redescription of *Hammondia hammondi* and its differentiation from *Toxoplasma gondii*

J.P. Dubey*, C. Sreekumar

United States Department of Agriculture, Beltsville Agricultural Research Center, Animal and Natural Resources Institute, Animal Parasitic Diseases Laboratory, Building 1001, BARC-East, Beltsville, MD 20705-2350, USA

Received 24 February 2003; received in revised form 26 May 2003; accepted 30 May 2003

Abstract

Hammondia hammondi is a protozoan parasite that, until 1975, was misidentified as *Toxoplasma gondii*. Recently, the validity of *H. hammondi* has been questioned. In this article, the authors redescribe the parasite and its life cycle, provide accession numbers to its specimens deposited in a museum, and distinguish it structurally and biologically from *T. gondii*. *Hammondia hammondi* was found to be structurally, biologically, and molecularly different from *T. gondii*.
Published by Elsevier Ltd. on behalf of Australian Society for Parasitology Inc.

Keywords: *Hammondia hammondi*; *Toxoplasma gondii*; Life cycle; Cats; Tachyzoites; Bradyzoites; Oocysts; Sporozoites

1. Introduction

Domestic cats (*Felis domesticus*) and other felids are important in the epidemiology of *Toxoplasma gondii* infection because they are the only hosts known to excrete the environmentally resistant oocysts (Dubey and Beattie, 1988; Tenter et al., 2000). *Toxoplasma gondii* oocysts are morphologically similar to oocysts of another coccidian, *Hammondia hammondi* (Frenkel and Dubey, 1975). The distinction between *H. hammondi* and *T. gondii* is important from an epidemiological perspective because all isolates of *T. gondii* are potentially pathogenic for humans and animals whereas *H. hammondi* is not known to cause clinical disease in any naturally infected host. Recently, Mehlhorn and Heydorn (2000) and Heydorn and Mehlhorn (2001) questioned the validity of *H. hammondi* as an organism distinct from *T. gondii*.

The objective of the present study was to redescribe *H. hammondi*, deposit specimens in a museum, and compare its biology with that of *T. gondii*.

2. Materials and methods

2.1. Parasite strains

Oocysts of the H.H. 34 strain of *H. hammondi* were obtained from Riahi et al. (1995). This strain was originally isolated in 1989 by Dr J.K. Frenkel from a domestic cat from Kansas City, Kansas, USA, and has been maintained in our laboratory since 1995 by passage between mice and cats. It was chosen for the study as the original type strain (CR-4) is now lost and because more is known of the H.H. 34 strain than any other isolate of *H. hammondi*. The VEG strain of *T. gondii* (Dubey et al., 1996) was used as control.

2.2. Experimental animals

Parasite-free cats from a closed colony were used; the history of this cat colony and its management were described previously (Dubey, 1995). Outbred Swiss Webster (SW) female albino mice were obtained from Taconic Farms, Germantown, New York. Gamma interferon gene knockout (KO) mice were obtained as reported by Dubey and Lindsay (1998). As KO mice lack the gene for the production of the cytokine gamma interferon, they are highly susceptible to *T. gondii* infection and were used to facilitate detection of low levels of infection. All animal

* Corresponding author. Tel.: +1-301-504-8128; fax: +1-301-504-9222.
E-mail address: jdubey@anri.barc.usda.gov (J.P. Dubey).

0020-7519/$30.00 Published by Elsevier Ltd. on behalf of Australian Society for Parasitology Inc.
doi:10.1016/S0020-7519(03)00141-3

experiments were performed according to Animal Care Protocols of the U.S. Department of Agriculture.

2.3. Bioassay for H. hammondi

Tachyzoites and bradyzoites were bioassayed in cats. Additionally, oocysts were bioassayed in SW and KO mice to study their infectivity.

Tissues of mice inoculated with *H. hammondi* stages (tachyzoites, bradyzoites, and sporozoites) were fed to cats and faeces of the cats were examined for oocyst shedding 3–30 days p.i. Oocysts were sporulated in 2% sulphuric acid or 2.5% potassium dichromate and after washing, were inoculated orally or s.c. into mice.

Tissues of acutely (containing tachyzoites) and chronically (containing bradyzoites) infected mice were bioassayed in cats. For this, 50 KO mice were each fed approximately 10^4 *H. hammondi* oocysts and 7, 8, 9, 10 and 12 days later, six mice were killed each day. The feet, skin and skull were removed, the carcasses were homogenised in a blender and the homogenate from each group of six mice was fed to two cats (Table 1). Faeces of cats were examined for 21 days for oocyst shedding.

Cats that did not shed oocysts (Table 1) after being fed mice acutely infected with *H. hammondi* were infected a second time using mice containing demonstrable tissue cysts to determine if they were not immune to *H. hammondi* before use in experiments. For this, five cats (numbers 685, 690, 691, 692, and 693) were fed tissues of mice that had been fed *H. hammondi* oocysts 33 days before (Table 1).

Extra-intestinal tissues of nine cats that had shed *H. hammondi* oocysts (Table 1) were subinoculated into KO mice. For this, portions of mesenteric lymph nodes, spleen, liver, lung, heart, and brain were homogenised in saline and inoculated s.c. into two to five KO mice. The recipient mice were observed for at least 30 days, their sera were examined for antibodies to *T. gondii* (see Section 2.9), and their brains and muscles were examined microscopically for the presence of tissue cysts.

To determine if corticosteroid administration could alter tissue localisation of *H. hammondi* in the definitive host, six cats that had shed *H. hammondi* oocysts in faeces (Table 1) were administered 40 mg/kg of methyl prednisolone acetate (Upjohn) intramuscularly.

2.4. Infectivity of H. hammondi to mice

To determine the infectivity of tachyzoites, portions of mesenteric lymph nodes and lungs of one of the KO mouse used in the cat bioassay (Section 2.3) were homogenised in 0.9% aqueous NaCl (saline) and inoculated s.c. into two KO mice. The presence of tachyzoites was ascertained by microscopic examination of smears of lungs and mesenteric lymph nodes. The recipient mice were observed for at least 30 days and their tissues were fed to cats to rule out the presence of infective tissue cysts.

In a separate experiment, SW mice were fed *H. hammondi* oocysts and euthanised 1, 2, 3, 4, 5, 6, 8, 11, or 15 days later. Their mesenteric lymph nodes were examined microscopically for the presence of organisms and bioassayed into two KO mice each. The KO mice were bled and tested for *T. gondii* antibodies 5 weeks p.i., euthanised and necropsied. Unstained muscle squash preparations from each mouse were examined for tissue cysts. Tissues were also fixed in formalin for histology.

To determine the infectivity of bradyzoites, three KO mice were fed oocysts of *H. hammondi* and after 6 weeks, their muscles containing tissue cysts were ground up in saline and inoculated into two KO mice each.

Infectivity of oocysts was determined by feeding the oocysts to SW and KO mice and examining their tissues 1–127 days later for evidence of *H. hammondi* stages (Table 2).

Table 1
Shedding of oocysts by cats fed tissues of *Hammondia hammondi* infected mice

Day of infection in mice[a]	Cat no.	Prepatent period for oocyst shedding[c]	Cats refed *Hammondia hammondi* tissue cysts	Prepatent period	Day of euthanasia[c]	Passage of cat tissues into KO mice
7	685	No oocysts	Yes	5	34(8)[e]	Neg
	690	No oocysts	Yes	5	34(8)[e]	Neg
8	691[b]	No oocysts	Yes	4	32(7)[e]	Neg
	692	No oocysts	Yes	7	33(8)[e]	Neg
9	693[b]	No oocysts	Yes	4	32(8)[e]	Neg
	694[b]	4	No	NA[d]	17	Neg
10	696[b]	5	No	NA	16	Neg
	697[b]	5	No	NA	16	Neg
12	698[b]	5	No	NA	14	Neg

[a] Days after feeding *Hammondia hammondi* oocysts to KO mice.
[b] Given 40 mg/kg methyl prednisolone acetate, after oocysts detected in faeces (day 12 for cats 694–698, day 31 for cats 691, 693).
[c] Primary infection.
[d] NA, not applicable.
[e] After first feeding. Numbers in parenthesis indicate days after challenge with tissue cysts.

Table 2
Tissue cyst formation in mice fed *Hammondia hammondi* oocysts

Day p.i.	No. of mice total (SW, KO)	BAG-1 positive tissues[a]						
		Ml	Li	Lu	K	B	H	Sk
1–5	20 (20,0)	0[b]	0	0	0	0	0	0
6	5 (3,2)	0	0	0	0	0	0	0
7	1 (0,1)	0	1[b]	1	0	0	1	1
8	3 (2,1)	0	0	0	0	0	0	0
9	1 (1,0)	0	0	0	0	0	0	0
10	3 (2,1)	0	2	2	0	0	2	3
11	4 (3,1)	0	2	4	0	1	4	4
14	4 (2,2)	1	1	4	1	0	4	4
15	1 (0,1)	1	0	1	0	0	1	1
17	1 (0,1)	1	1	1	0	0	1	1
19	4 (2,2)	1	0	3	1	1	4	4
22	1 (0,1)	NE[c]	1	1	NE	0	1	1
33	1 (0,1)	0	0	1	0	0	1	
70	1 (0,1)	0	0	1	0	0	1	1
84	1 (0,1)	0	0	1	0	0	1	1
123	1 (0,1)	0	0	1	0	0	1	1
127	1 (0,1)	0	0	1	0	0	1	1

[a] B, brain; H, heart; K, kidney; Li, liver; Lu, lung; Ml, mesenteric lymph nodes; Sk, skeletal muscle.
[b] No. of mice positive.
[c] NE, not examined.

2.5. Development of H. hammondi in cats

Ten newborn (2–10 days old) and 18 weaned cats were fed tissue cysts or bradyzoites freed from tissue cysts from chronically infected mice. To release bradyzoites from intramuscular cysts, heavily infected muscles were homogenised in saline using a blender, large particles removed by filtering with gauze, centrifuged, and fed to newborn cats by intubation. Weaned cats were fed muscles from heavily infected mice. Cats were euthanised on day 1 (6 cats), day 2 (three cats), day 3 (one cat), and days 4–21 p.i. (16 cats) and portions of their intestines, mesenteric lymph nodes, spleen, kidneys, liver, heart, lungs and brain were fixed in formalin or Karnovsky's fixative (Karnovsky, 1965). To study intestinal stages, the entire small intestine was slit open, divided into five equal portions and six specimens from each portion were fixed in formalin.

2.6. Histologic and immunohistologic examinations

Samples of intestines, mesenteric lymph nodes, spleen, liver, lungs, heart, kidney, muscles, and brain of cats and mice were fixed in neutral buffered 10% formalin. Paraffin-embedded sections were cut at 5 μm thickness, stained with haematoxylin and eosin (H&E) or periodic acid Schiff and counterstained with haematoxylin (PASH). Certain tissues were embedded in methacrylate, 1–3 μm sections were prepared and examined after staining with H&E or PASH.

Deparaffinised sections were stained with *T. gondii* antibodies. Tachyzoites and tissue cysts from *T. gondii* infected mice were used as controls. Tissue cysts were obtained from the brains of SW mice fed oocysts. Tachyzoites were obtained by intraperitoneal inoculation of KO mice with tissue cysts. Oocysts were obtained by feeding brains of chronically infected mice to cats. Immunohistochemical staining was performed using the Dako Envision peroxidase (Dako) rabbit kit and Envision system. Two types of rabbit antibodies (polyclonal and anti-BAG-1) were used. To obtain polyclonal anti-*T. gondii* antibodies, a 6-week-old New Zealand white rabbit (Covance Research Products Inc.), was fed 100 oocysts and serum was obtained on 30 day p.i. A 1:2,000 dilution of this serum was used. The bradyzoite-specific (BAG-1, also called BAG-5) rabbit antibody reported by McAllister et al. (1996) was used at a 1:10,000 serum dilution; this antibody does not stain tachyzoites but does stain bradyzoites of both *T. gondii*, *Neospora caninum* (McAllister et al., 1996) and *H. hammondi* (see results of present study).

2.7. In vitro cultivation of H. hammondi

Attempts were made to cultivate *H. hammondi* in M617 (bovine monocyte) cells (Dubey et al., 1999) and CV1 cells (African Green monkey kidney cells, ATCC CCL-70) using sporozoites, tachyzoites, and bradyzoites. Sporozoites were obtained by treating sporulated oocysts with 5.25% sodium hypochlorite, vortexing with glass beads (Microbeads, Ferro Corporation) and subsequent incubation in an excystation medium [sodium taurocholate 500 mg, trypsin (1:250) 25 mg in 100 ml saline, pH 7.5] at 37 °C. The released sporozoites were filtered through a 5 μm membrane and washed in RPMI 1640 medium. To obtain tachyzoites, sporulated oocysts were fed to KO or SW mice; these mice were killed 1, 2, 3, 4, 5, 6, 7, 8, 11, or 15 days later (Section 2.4). Mesenteric lymph nodes were removed from these mice and homogenised in tissue culture medium. Bradyzoites were obtained by homogenising muscles of chronically infected mice containing tissue cysts. The homogenised suspensions were washed once in growth medium by centrifugation. The pellets were resuspended in growth medium and layered over 50% confluent monolayers of CV1 and M617 cells grown on 12 mm coverslips in 24 well plates. The medium was changed after overnight adsorption. Cultures were maintained at 37 °C for up to 10 weeks and examined for the establishment of infection. Periodically, coverslips were removed and stained with Giemsa after fixation with Bouin's fixative. Attempts were made to passage the infection by inoculating the supernatant from wells containing released parasites onto fresh monolayers. To rule out contamination with *T. gondii*, the pooled culture supernates were inoculated s.c. into KO mice and the mice were observed for signs of infection and seroconversion. Coverslips were also stained immunohistochemically using BAG-1 antibody.

2.8. Transmission electron microscopy

Specimens were fixed in Karnovsky's fixative or in formalin, post-fixed in osmium, and processed for transmission electron microscopy (TEM). For TEM of tachyzoites, mesenteric lymph nodes from a KO mouse fed oocysts 5 days earlier and for study of tissues cysts, abdominal muscle from a KO mouse fed *H. hammondi* oocysts 70 days earlier were used. For study of schizonts and gamonts, ileal tissue from cats fed tissue cysts 7 days earlier were used.

2.9. Serologic examination

Antibodies to *T. gondii* and *H. hammondi* were assayed by the modified agglutination test (MAT) for *T. gondii*, as described by Dubey and Desmonts (1987). In MAT, killed, whole *T. gondii* tachyzoites are used as antigen and it detects antibodies to both *T. gondii* and *H. hammondi*.

2.10. Morphologic comparison between H. hammondi and T. gondii

The morphometry of tachyzoites, bradyzoites, and sporozoites of both *H. hammondi* and *T. gondii* were compared using identical techniques. For cytologic studies, tachyzoites in impression smears of mesenteric lymph nodes of mice fed with oocysts 4–5 days earlier were measured. Bradyzoites mechanically released from tissue cysts were smeared on glass slides. Sporozoites were excysted from sporulated oocysts, washed, added to cell culture, and fixed 30 min later. All specimens were fixed in Bouin's fixative and stained with Giemsa. They were measured by one observer using the same micrometer and the same microscope in order to provide a statistically sound means by which to compare their morphology, free from possible sampling artifacts associated with histologic techniques.

3. Results

3.1. In vitro cultivation

Tachyzoites (Fig. 1A, B) and sporozoites (Fig. 1C) of *H. hammondi* were able to initiate infection in both CV1 and M617 cells, but bradyzoites (Fig. 1D) did not. When tachyzoites were added to monolayers, they invaded the cells and endodyogenic forms containing two (Fig. 1E) parasites could be seen by 9 h. Forms resembling bradyzoites, characterized by terminal nuclei could also be seen in some cells (Fig. 1F). By 45 h, most of the cells contained four parasites while some had parasitophorous vacuoles containing three parasites (Fig. 1G). By 11 days, structures resembling tissue cysts were seen (Fig. 1H). The nuclei of the intracellular zoites were distinctly terminal in location. During this time there was release of numerous free zoites into the culture supernatant. By 35 days, the intracellular tissue cysts had distinct and definite outer wall and each contained numerous zoites (Fig. 1I); they stained positively with BAG-1 antibody (Fig. 1J). However, as time progressed, the number of infected cells in culture decreased. By 44 days, only few tissue cysts remained in culture and they were BAG-1 antibody positive. Even at this stage, there were a few host cells that contained early multiplying stages (either singly or in pairs), which also stained with BAG-1 antibody. The stages of *H. hammondi* were gradually lost from culture, and after 66 days they could not be identified in the stained preparations.

Lymph nodes from KO mice, collected 1, 2, 3, 4, 5, 6, 7, 8, 11, and 15 days after oral infection with oocysts were able to infect monolayers. However, tissue cysts were not found in the cultures, to which lymph node homogenates collected on days 1 and 2 after infection were added. Only parasites in early stages of division were noticed, while tissue cysts were already identifiable in cultures infected subsequently with lymph nodes collected from day 3 onwards. Parasites were not found in cell cultures into which free zoites from culture supernatant were added.

Results of infection with sporozoites were similar to those initiated with tachyzoites, with tissue cysts being noticed in 25 days.

With bradyzoite inoculation, some of the host cells were found to contain intact organisms with terminal nuclei, singly as well as in pairs (Fig. 1D), in coverslip preparations stained after 19 h, but not later. However, apparently intact free bradyzoites could be seen in cultures for up to 10 days.

Stages of *H. hammondi* or antibodies to *T. gondii* were not found in KO mice inoculated with the pooled culture supernatant and observed for 2 months.

3.2. Infectivity of tachyzoites and tissue cysts to cats

The four cats fed tissues of KO mice infected 7 or 8 days earlier did not shed oocysts whereas one of the two cats fed mice infected 9 days earlier, and all four cats fed mice infected 10 or 12 days earlier shed oocysts (Table 1). The five cats that had not shed oocysts after ingesting acutely infected mice shed oocysts when fed chronically infected mice (Table 1). The prepatent periods were 4–7 days (Table 1). Tissue homogenates of infected cats were not infective to KO mice as indicated by bioassays and histologic examination.

3.3. Infectivity of H. hammondi to mice

3.3.1. Infectivity of tachyzoites

The KO mice inoculated with tissue homogenates of KO mice killed 5–15 days p.i. did not develop antibodies to *T. gondii,* nor was *H. hammondi* found in their tissues. However, *H. hammondi* tissue cysts were found in KO mice inoculated with the lymph node homogenates from mice

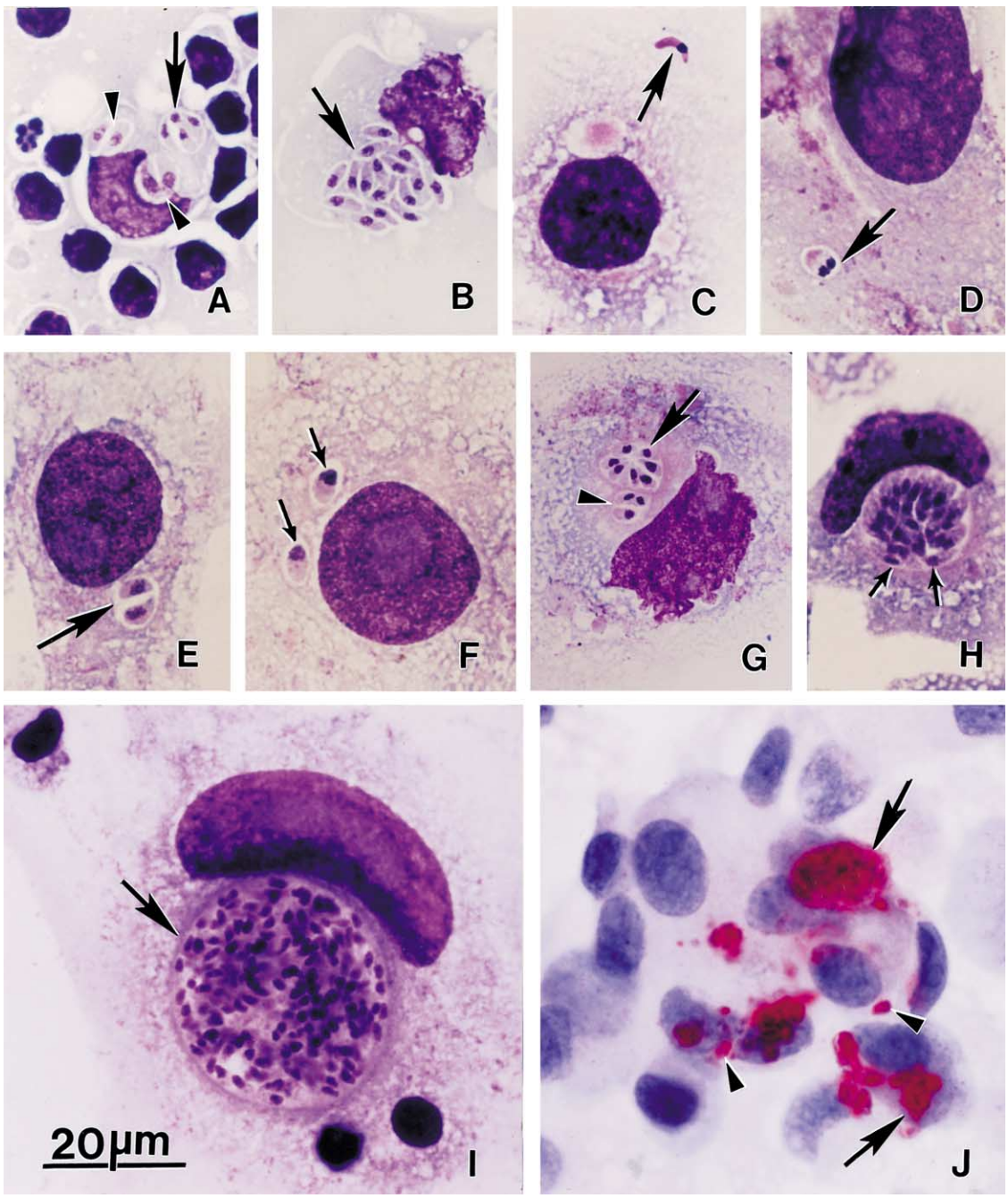

Fig. 1. Asexual stages of *Hammondia hammondi*. Bar applies to all parts. A–I, Giemsa stain, J, immunohistochemical stain with BAG-1 antibody. (A&B) Tachyzoites (arrows) in smears of mesenteric lymph node of KO mouse, 5 days p.i. Note paired organisms (arrowheads). (C) A sporozoite (arrow), 30 min after inoculation of CV1 cells. (D) Organisms 19 h after seeding CV1 cells with bradyzoites released from intramuscular cysts. Note the terminal nuclei. It is uncertain if two organisms entered the same vacuole. (E–J) Organisms in M 617 cells after seeding with tachyzoites. (E) Paired tachyzoites (arrow) in a vacuole, 9 h p.i. (F) Two separate organisms with terminal nuclei (arrows), 9 h p.i. (G) Asynchronous division resulting in vacuoles containing three (arrowhead) and 7 (arrow) parasites with terminal nuclei, 45 h p.i. (H) A tissue cyst-like structure, 11 days p.i. The organisms show terminal nuclei (arrows). Tissue cyst wall is not visible. (I) A tissue cyst, 35 days p.i. Note a clear tissue cyst wall (arrow). (J) Individual (arrowheads) and groups (arrows) of organisms, 26 days p.i.

that were fed oocysts 1 (two out of two mice) and 4 (one out of two mice) days earlier.

3.3.2. Infectivity of bradyzoites

Stages of *H. hammondi* were not seen in the six KO mice inoculated with *H. hammondi* bradyzoites released from intramuscular tissue cysts.

3.3.3. Infectivity of oocysts

The KO mice fed *H. hammondi* oocysts became ill and tachyzoites were seen in their mesenteric lymph nodes, lungs, and other organs. Histologically, only tachyzoites were seen in tissues of mice fed oocysts and examined 1–6 days p.i. These organisms reacted with polyclonal anti-*T. gondii* antibodies but not with anti-BAG-1 antibody (Table 2).

The BAG-1 positive organisms were first detected in a KO mouse killed 7 days p.i., but were not seen in four other mice examined 8 and 9 days p.i. (Table 2). BAG-1 positive organisms were seen consistently in lungs, heart, and skeletal muscles of mice killed 10–127 days p.i. (Table 2). Both individual and groups of organisms were BAG-1 positive and in H&E-stained preparations, these groups equated with tissue cysts. Occasionally, many tissue cysts were seen in mesenteric lymph nodes of mice killed 15–19 days p.i. Organisms within groups in mice examined up to 11 days p.i. were PAS-negative; they became PAS-positive beginning 14 days p.i., with the intensity of PAS staining increasing with the duration of infection up to 35 days p.i. when observation ceased.

3.4. Development of H. hammondi in cats

Schizonts and gamonts were seen in intestine of cats beginning 4 days p.i. (see description in Section 3.5).

3.5. Redescription of H. hammondi

Tachyzoites and tissue cysts are the only asexual stages present in intermediate hosts and in cell cultures (Figs. 1–5). Tachyzoites were found in many host cells and they divided by endodyogeny (Figs. 1 and 2). Tachyzoites were lunate with a centrally located nucleus (Fig. 1A, B). They were 5.0×1.7 μm ($4–6 \times 1–2$, $n = 50$) in size. Ultrastructurally, tachyzoites contained a conoid, rhoptries, micronemes, a mitochondrium, dense granules, and a centrally located nucleus (Fig. 2). Micronemes were up to 175 nm long, located mostly anterior to the nucleus, and up to 20 were seen in one plane of a section. The rhoptries extended up to posterior of the nucleus and as many as four were seen in one plane of a section. Rhoptries were long necked with a bulbous end that was up to 220 nm thick. The rhoptry contents were electron-dense (Fig. 2).

Tissue cysts (Fig. 3) were present in several organs but were found most frequently in muscles and lungs (Table 2). The tissue cyst wall was about 0.5 μm thick with thicker polar ends and enclosed several hundred slender bradyzoites (Fig. 3A, B). Bradyzoites measured 5.9×1.3 μm ($5–7 \times 1–2$, $n = 50$) in size. The nucleus was located terminally in bradyzoites (Fig. 3I). Ultrastructurally, the outer tissue cyst wall layer (parasitophorous vacuolar membrane, PVM) was highly infolded and lined by an electron-dense material (Fig. 4). The PVM was abutted with the myocyte cytoplasm. Bradyzoites contained organelles commonly found in coccidian merozoites including a conoid, rhoptries, a mitochondrium, micronemes, numerous amylopectin granules, and a nucleus located at the basal (nonconoidal) end. The rhoptries were few in numbers (only two were seen in a given section) and their contents were electron-dense (Fig. 4). The micronemes were approximately 270 nm long and were dispersed anterior to the nucleus.

Only schizonts and gamonts were found in the definitive host, and they were located in the small intestinal epithelial cells (Fig. 5). Although the entire villi were parasitised in heavily infected cats, most parasites were located in enterocytes towards the distal (luminal) end of the villous. All stages were located in the host cell cytoplasm above the nucleus (Fig. 5A). Schizonts were first seen day 4 p.i. The schizont nucleus divided into several nuclei before merozoites were formed. An eosinophilic residual body was present in a few schizonts (Fig. 5D). Mature schizonts were up to 12 μm in diameter. Merozoites were banana-to-sickle-shaped (Fig. 5B–D, G–K) and up to 16 merozoites were present in a schizont (Fig. 5I). In Giemsa-stained smears, merozoites were 5.5×1.4 μm ($4.5–7.5 \times 1–2$, $n = 100$) in size (Fig. 5I–K). Merozoites in histological sections were $4–6 \times 1$ μm in size (Fig. 5B–D). They varied in shape and size but it was not determined if merozoites belonged to more than one generation. Schizonts and merozoites were PAS-negative. Microgamonts were up to 15×10 μm in size (Fig. 5F–H) and contained up to 16 gametes (Fig. 5L). The microgametes were approximately 5 μm long excluding the flagella (Fig. 5M); the flagella were about 10 μm long in Giemsa stained smears. Macrogamonts were round to oval and contained a central nucleus, and measured up to 10 μm in diameter (Fig. 5N).

Oocysts were shed 4–7 days after ingesting tissue cysts. Unsporulated oocysts were colourless, spherical to oblong with two layered thin oocyst walls (Fig. 5O). In some oocysts, one end was narrower than the other (Fig. 5P). A few granules were present between the oocyst wall and the sporont, which occupied most of the oocyst interior (Fig. 5O). Unsporulated oocysts were 12.4×11.0 μm ($11.5–14 \times 10–12$; $n = 100$) in size, with a length–width ratio of 1.2–1.0. Oocysts sporulated in 2.5% potassium dichromate were round to ellipsoidal and measured 14.6×11.6 μm ($14–16 \times 10–14$, $n = 100$) in size with a length–width ratio of 1.2 (1.1–1.4) (Fig. 5Q, R). Each sporulated oocyst contained two sporocysts. Sporocysts released from oocysts were 10×7 μm ($9.5–10.5 \times 6–8$, $n = 100$) in size, with a length–width ratio of 1.4 (1.2–1.6). Occasionally oocysts with one sporocyst containing eight sporozoites or oocysts containing two dissimilar sporocysts were seen. Each sporocyst had four banana-shaped slender sporozoites with a compact or granular sporocyst residuum. Excysted sporozoites in Giemsa-stained smears were 6.3×1.3 μm ($5–8 \times 1–2$, $n = 50$) in size (Fig. 1C). Sporozoites were often curved in shape and the nucleus was located often towards the anterior pointed end. In Giemsa stained smears, the tip of the sporozoite was stained prominently.

The schizonts and gamonts did not react with BAG-1 antibody at all. They either did not react or reacted faintly with polyclonal anti-*T. gondii* antibodies. Ultrastructurally, schizonts and gamonts were located in a parasitophorous vacuole (PV) of the cytoplasm of enterocytes just below the microvilli; microtubules were not seen in these vacuoles. Merozoites were produced by schizogony. The youngest schizont was 6 μm in diameter and contained two nuclei. Merozoite formation had started in some schizonts at

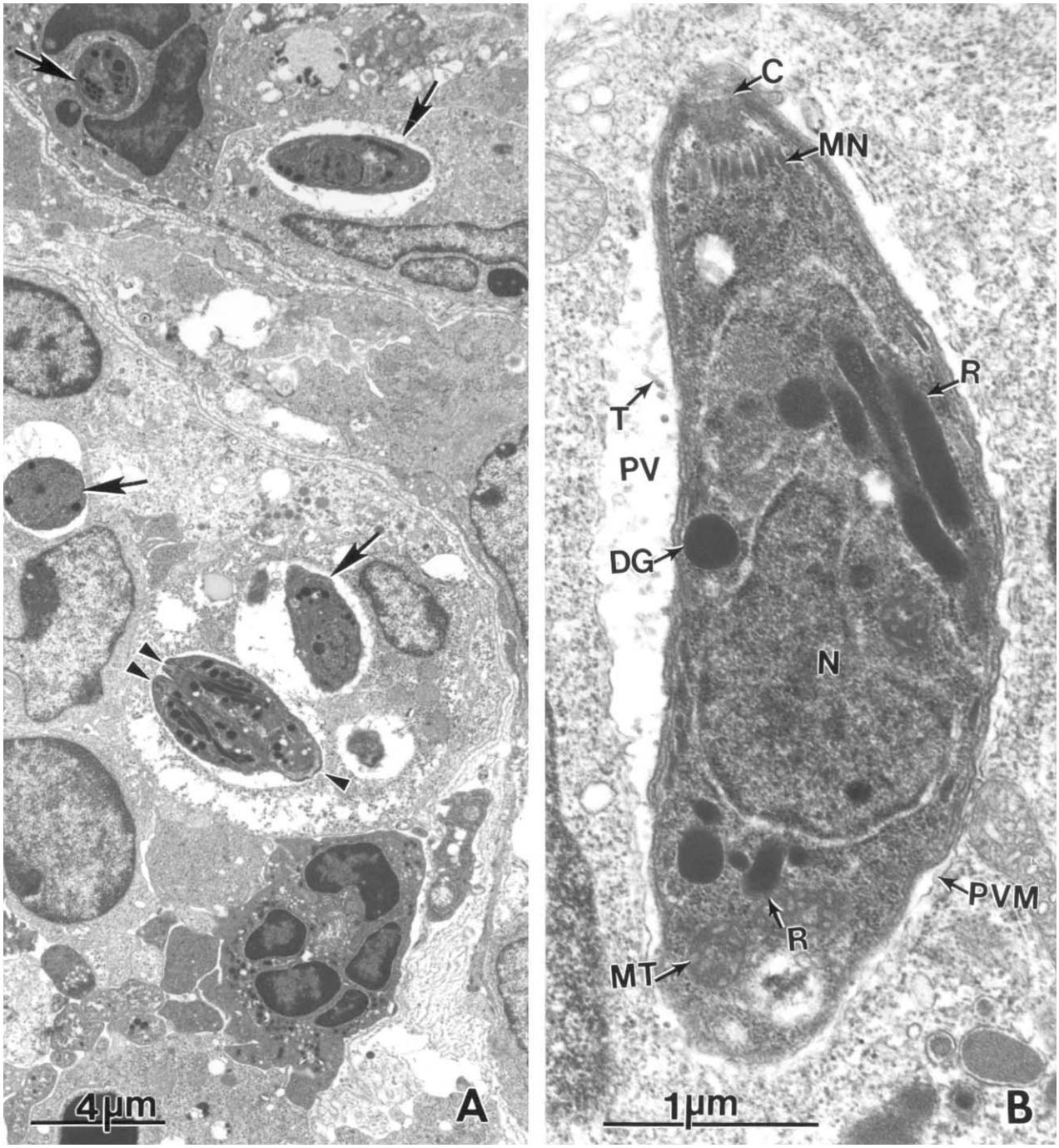

Fig. 2. TEM of *Hammondia hammondi* tachyzoites in mesenteric lymph node of a KO mouse, 5 day p.i. (A) Individual (arrows) and dividing (arrowheads) tachyzoites. (B) Longitudinal section of a tachyzoite. This tachyzoite is separated from the host cell cytoplasm by a parasitophorous vacuole (PV) containing tubular network (T) and demarcated from the host cell cytoplasm by a thin parasitophorous vacuolar membrane (PVM). Note a conoid (C), few micronemes (MN), rhoptries (R), nucleus (N), dense granules (DG), and a mitochondrium (MT).

the three-nucleated stage. A residual body was seen in some schizonts (Fig. 6). Mature merozoites were approximately 5×1.2 μm in size and contained micronemes, a few rhoptries, a conoid, and nucleus located towards the basal end. Macrogamonts contained a centrally located nucleus, lipid bodies, amylopectin granules, and wall-forming bodies. Microgamonts contained up to 16 nuclei that were peripherally located. The nuclei of microgamonts were much smaller in size than those of schizonts. A central residual body contained amylopectin granules.

3.6. Deposition of specimens

The following *H. hammondi* neotypes have been deposited in the United States National Parasite Collection (USNPC), Beltsville, MD 20705, USA. (a) A composite H&E

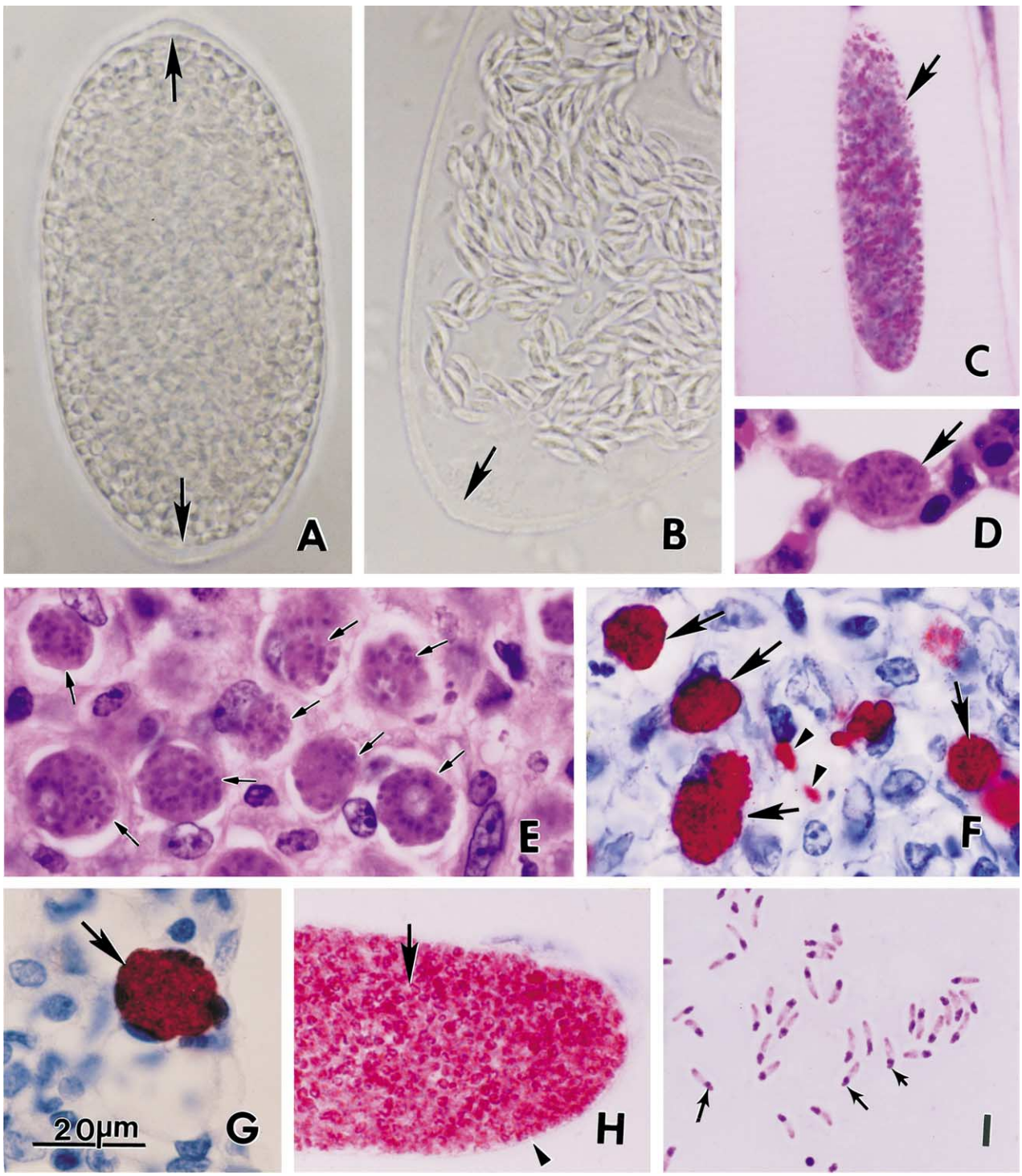

Fig. 3. Tissue cysts and bradyzoites of *Hammondia hammondi* in tissues of KO mice fed oocysts. Bar applies to all parts. (A&B) Live tissue cysts from abdominal muscle with a thin cyst wall that appears thicker at the poles (arrows), 176 days p.i. Unstained. The tissue cyst in B was ruptured mechanically to release some bradyzoites. (C) Intramuscular tissue cyst containing numerous PAS-positive bradyzoites (arrow), 19 days p.i. (D) Tissue cyst in alveolar septum of lung, 15 days p.i. Note thin cyst wall (arrow). H&E. (E) Eight tissue cysts (arrows) in mesenteric lymph node, 15 days p.i. H&E. (F) BAG-1 positive groups (arrows) and individual bradyzoites (arrowheads) in mesenteric lymph node, 17 days p.i. Immunohistochemical stain with BAG-1 antibody. (G) Tissue cyst in lung, 33 days p.i. Immunohistochemical stain with BAG-1 antibody. (H) Tissue cyst containing numerous BAG-1 positive bradyzoites (arrow) enclosed in a thin BAG-1 negative cyst wall (arrowhead) in skeletal muscle, 123 day p.i. Immunohistochemical stain with BAG-1 antibody. (I) Bradyzoites released from a tissue cyst from skeletal muscle of a KO mouse, 174 days p.i. Bouin's fixed. Giemsa stain. Note terminal nuclei (arrows).

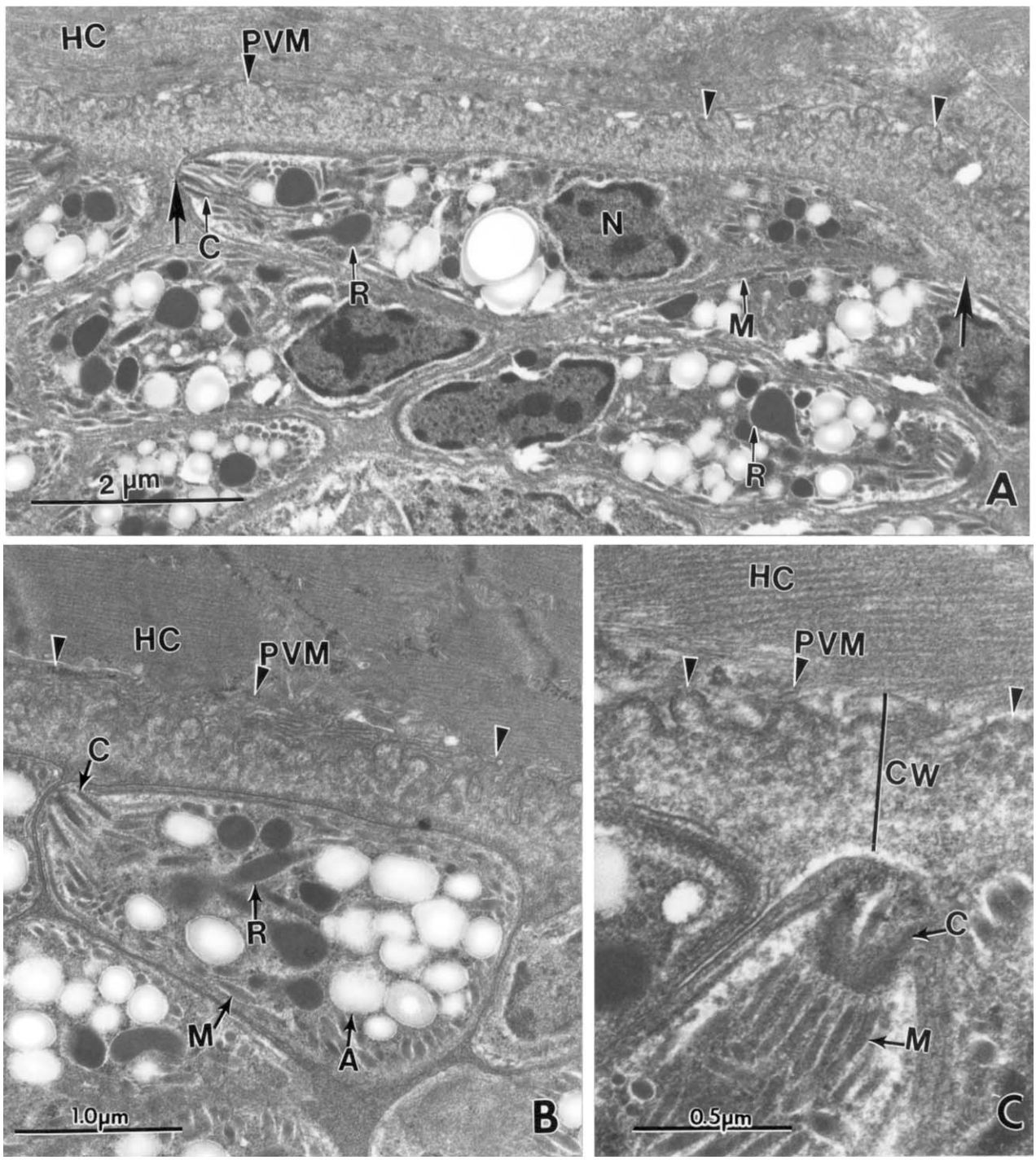

Fig. 4. TEM of tissue cysts and bradyzoites of *Hammondia hammondi* in skeletal muscle of KO mouse, 70 days p.i. Note that the outer membrane (PVM, arrowheads) of the cyst wall (CW) is in direct contact with the host cell (HC) and the bradyzoites are juxtaposed with the inner layer of the cyst wall. (A) Longitudinal section of a bradyzoite (large arrows) oriented along the PVM (arrowheads) in a myocyte (HC). Also note numerous amylopectin granules (A), many micronemes (M), few rhoptries (R), a conoid (C), and a nucleus (N) in bradyzoites. (B&C) Higher magnification of the conoidal ends of bradyzoites.

stained slide of mesenteric lymph node and small intestine of SW mice fed oocysts, muscle of a SW mouse fed oocysts, and small intestine of a cat fed tissue cysts. Accession No. 93684. (b) Wet, formalin fixed muscle from a KO mouse containing tissue cysts, 127 days p.i. Accession No. 92685. (c) Wet, formalin fixed, small intestine of a cat containing schizonts and gamonts, 7 days p.i. Accession No. 92686. (d) Formalin-fixed, sporulated oocysts of *H. hammondi* from the faeces of a cat. Accession No. 92687. (e) Photos of unsporulated and sporulated oocysts. Accession No. 92688.

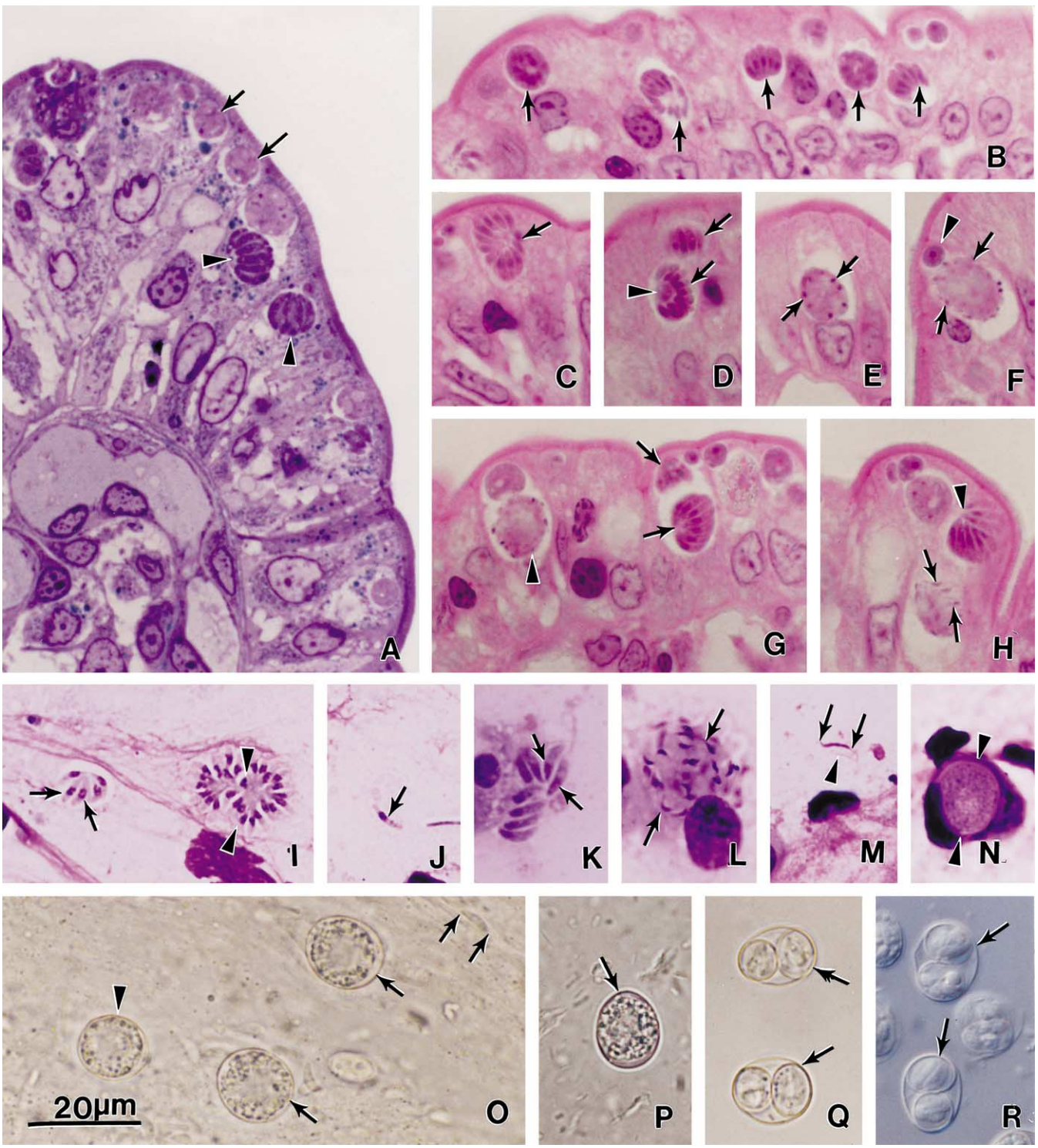

Fig. 5. Coccidian stages of *Hammondia hammondi* in sections (A–H) and smears (I–O) of small intestine of cats, 7 days p.i. Oocysts from faeces of cats (P–R) (A, 1 μm section. Toluidine Blue stain. B-H, 2–3 μm methacrylate-embedded sections stained with H&E, I–N, Giemsa stain, O–R, unstained). Bar applies to all parts. (A) Intestinal villus showing macrogamonts (arrows) and schizonts (arrowheads) located above the enterocyte nucleus. (B) Several schizonts (arrows). (C) Schizont with peripherally arranged merozoites (arrow). (D) Two schizonts (arrows), one with a residual body (arrowhead). (E) Microgamont with multiple nuclei (arrows). (F) Microgamont with several nuclei (arrows) and a macrogamont (arrowhead). (G) Schizonts (arrows) and a microgamont (arrowhead). (H) Schizont (arrowhead) and a mature microgamont with microgametes (arrows). (I) Two schizonts. The schizont on the left has five merozoites that have central nuclei (arrows). The schizont on the right has merozoites forming at the periphery (arrowheads). (J) Elongated merozoite (arrow) with nucleus located towards one end. (K) Merozoites with terminal nuclei (arrows). (L) Microgamont with several microgametes (arrows). (M) A microgamete (arrows) with two flagella that are faintly stained (arrowhead). (N) A macrogamont (arrowheads). (O) Three unsporulated oocysts. The oocyst on the left (arrowhead) is much smaller (11 μm wide) compared with two oocysts (14 μm wide) on the right (arrows). A merozoite (double arrows) is also shown. (P) Unsporulated oocyst with one end narrower (arrow) than the other. (Q) Two sporulated oocysts (arrows). (R) Sporulated oocysts (arrows), Nomarsky interference microscopic view.

Fig. 6. TEM of two mature schizonts of *Hammondia hammondi* in enterocytes of ileum of a cat. The schizont on the right has a residual body (RB). The schizont on the left is located close to the host cell nucleus (HCN). These schizonts are enclosed in a relatively thick parasitophorous vacuolar membrane (PVM) and the parasitophorous vacuoles (PV) are devoid of tubular network. Note rarity of rhoptries. Rhoptry (R) is visible in only one merozoite and its bulbous end is directed towards the conoidal end of the zoite. Note a conoid (C), micronemes (MN), mitochondrium (MT) and terminal nucleus (N) towards the basal end of the merozoites. Bar applies to both schizonts.

4. Discussion

4.1. Structures and life cycle of H. hammondi

Serologic reactivity between *H. hammondi* and *T. gondii* (Frenkel and Dubey, 1975) was used in the present investigation as an aid to study the life cycle of *H. hammondi* in mice. Mice inoculated with *H. hammondi* oocysts developed antibodies (MAT, ≥1:25) to *T. gondii*, but mice inoculated with tachyzoites or bradyzoites remained seronegative. Furthermore, *H. hammondi* was not found in the tissues of these seronegative mice. Immunohistochemically, both tachyzoites and bradyzoites reacted with *T. gondii* polyclonal antibodies, but only bradyzoites reacted with the BAG-1 antibody. McAllister et al. (1996) reported that BAG-1 antibody derived from

T. gondii bradyzoites is not species-specific, but stage-specific because it reacted with bradyzoites of *Neospora caninum* and *T. gondii* but not with tachyzoites of either parasite. We also report that BAG-1 antibody reacts with bradyzoites, but not with tachyzoites of *H. hammondi*.

In the present study, tachyzoites of *H. hammondi* were seen in the small intestinal lamina propria and mesenteric lymph nodes of SW or KO mice 1 day after feeding oocysts. Tachyzoites replicated in tissues of mice during the first 2 weeks p.i. mostly in visceral tissues. In H&E-stained sections, intramuscular groups with the morphology of tissue cysts were first seen 10 days p.i. The BAG-1 positive organisms were first detected in a mouse 7 days p.i., but were consistently seen only after 10 days p.i. (Table 2). The finding of tissue cysts in mesenteric lymph nodes and lungs of mice in the present study was unexpected because these were not reported previously in histologic sections (Frenkel and Dubey, 1975). However, Dubey and Streitel (1976) and Shimura and Ito (1986) had reported biologic evidence for tissue cysts in visceral tissues. Dubey and Streitel (1976) reported that cats fed spleen, mesenteric lymph nodes, kidneys and livers of mice 14–87 days p.i. shed *H. hammondi* oocysts. In the study of Shimura and Ito (1986), cats fed mice that had been orally inoculated with *H. hammondi* oocysts 9 days earlier did not shed oocysts, whereas cats fed mice that had been fed oocysts 10 days before, did shed oocysts. Based on the present study, and those published previously, it is concluded that *H. hammondi* forms tissue cysts around the10th day after feeding oocysts, and that tachyzoites are not infective for cats.

In the present study, KO mice lacking the gene for the production of the cytokine gamma interferon were used to facilitate detection of low levels of infection. These immunosuppressed mice are highly susceptible to *T. gondii* infection. Although intensity of *H. hammondi* infection in KO mice was higher than in SW mice, the tissue localisation was not affected. For example, even in heavily parasitised mice, *H. hammondi* tissue cysts were rarely found in brains, irrespective of duration of infection or the type of the mouse used (Table 2).

The ability of sporozoites, tachyzoites, and bradyzoites of *H. hammondi* to adapt to in vitro culture was studied. It was found that both tachyzoites and sporozoites were able to infect both CV1 and M617 cells, while free bradyzoites were not able to replicate in cell cultures. However, the parasite could not be maintained indefinitely as it formed structures resembling bradyzoites and tissue cysts. Tachyzoites and sporozoites behaved in a similar manner, in that they both formed tissue cysts. The presence of organisms with terminal nuclei in parasitophorous vacuoles, 9 h after infection with tachyzoites indicated that the stage conversion to bradyzoite was rapid. Though the tissue cysts ruptured periodically releasing zoites in culture medium, these were not subsequently infective to fresh cultures, as were the free bradyzoites released from tissue cysts from the muscles of mice infected with *H. hammondi*.

Results of the present study confirm the findings of Sheffield et al. (1976) and Riahi et al. (1995) that *H. hammondi* cannot be maintained indefinitely in culture. In both these reports, the cultures were initiated by sporozoites. Additionally, we found that the cultures could be initiated with tachyzoites obtained from mesenteric lymph nodes of mice fed oocysts 1–15 days earlier. The reason why tachyzoites from mice were not infective to other mice, but infective to cell cultures is unknown. Similarly the presence of BAG-1 positive parasites in stages of early division in chronically infected cultures (after 44 days) could not be explained, especially in the light of the fact that extracellular stages released from ruptured tissue cysts were consistently non-infective to fresh cultures. It was also not known why the infective stages in murine tissue homogenates, obtained 1 and 2 days after oocyst infection, did not produce tissue cysts in culture.

In the present study, *H. hammondi* stages were not seen in H&E stained sections of any tissue of 10 cats 1–3 days p.i. The schizants found in the present study corresponded to *T. gondii* types D and E schizonts in the intestine of cats (Dubey and Frenkel, 1972). However, *T. gondii* types A to C that precede types D and E were not found. Frenkel and Dubey (1975) also did not find intestinal stages in cats killed 1–3 days p.i. Schizonts and gamonts were seen starting day 4 p.i. The present ultrastructural study indicated that *H. hammondi* merozoites were produced by schizogony. The earliest merozoite formation was seen at the three-nucleated stage. The merozoites varied in shape and size ranging from 4 to 7 μm and the position of the nucleus was central to terminal. Whether these merozoites belonged to morphologically distinct generations was not studied. Tissue cysts and tachyzoites were not identified in cats, histologically, immunohistochemically or by bioassay.

The minimal prepatent period of *H. hammondi* was 4 days in the present study compared with 5–17 days reported in previous studies (Dubey, 1975a,b; Frenkel and Dubey, 1975; Wallace, 1975; Dubey and Streitel, 1976; Rommel and von Seyerl, 1976; Eydelloth, 1977; Mason, 1978; Shimura and Ito, 1986). *Hammondia hammondi* oocysts in the present study were also slightly bigger in size than *H. hammondi* oocysts reported by Frenkel and Dubey (1975), Mason (1978) and Shimura and Ito (1986). The number of oocysts measured by Frenkel and Dubey (1975) was not stated. Mason (1978) reported average measurements of 40 unsporulated oocysts as 12.1 × 10.6 μm and 30 sporulated oocysts as 12.3 × 10.8 μm. Shimura and Ito (1986) reported average measurements of 100 sporulated oocysts as 13 × 11.4 (11.5–14 × 9.5–13) μm and Rommel and von Seyerl (1976) gave measurements of unsporulated oocysts as 13.8 × 12.2 (11.7–17.5 × 10.2–14.6) μm; whether minor differences among measurements of *H. hammondi* oocysts in these reports are related to strains of the parasite, stage (sporulated versus unsporulated) measured, or the techniques of measurements needs further study. Unsporulated oocysts are a little smaller in size than

sporulated oocysts because the oocyst wall is stretched after sporulation because of the large size of sporocysts. The medium in which sporulation occurs also affects the shape of sporulated oocysts. The original shape of the oocyst is better retained in 2.5% potassium dichromate than in 2% sulphuric acid. In our opinion, more consistent measurements are obtained from unsporulated than sporulated oocysts.

4.2. Comparison of H. hammondi and T. gondii

Results of the present study, and those summarised previously by Frenkel and Dubey (2000) show that *H. hammondi* is structurally, biologically, antigenically, and genetically distinct from *T. gondii*. Mehlhorn and Heydorn (2000) and Heydorn and Mehlhorn (2001) questioned the validity of this conclusion. We will attempt to address some of their concerns.

It is clear that *H. hammondi* and *T. gondii* are structurally similar but not identical parasites. Although tachyzoites, bradyzoites, oocysts, and sporozoites of *T. gondii* are about 1 μm smaller than those of *H. hammondi* (Table 3) they appear morphologically similar under the light microscope. Ultrastructurally, there are two consistent differences between their tachyzoites and sporozoites. Rhoptries in *H. hammondi* tachyzoites are electron-dense whereas those of *T. gondii* tachyzoites are electron-lucent. Heydorn and Mehlhorn (2001) considered this difference due to

Table 3
Comparison of *Hammondia hammondi* and *Toxoplasma gondii*

	Hammondia hammondi	*Toxoplasma gondii*	References (Pertaining to *Hammondia hammondi*)
Definitive host	Cats	Cats	Frenkel and Dubey (1975); Wallace (1975); Rommel and Seyerl (1976); Christie and Dubey (1977); Eydelloth (1977); Ogassawara et al. (1985)
Extra-intestinal development	Absent	Present	Frenkel and Dubey (1975); Dubey (1975b); Present study
Tachyzoites	Absent	Present	Frenkel and Dubey (1975); Present study
Tissue cysts	Absent	Present	Frenkel and Dubey (1975); Present study
Tachyzoite infectivity (oral)	No	Yes	Dubey and Streitel (1975); Shimura and Ito (1986); Present study
Oocyst infectivity (oral)	No	Yes	Frenkel and Dubey (1975); Christie et al. (1977); Mason (1978); Ogassawara et al. (1985); Shimura and Ito (1986)
Prepatent period (minimum)	4 days	3 days	Present study
Pathogenicity	Nonpathogenic	Pathogenic	Frenkel and Dubey (1975); Dubey (1975b)
Intermediate hosts			
Natural	Limited (mice, rats, goats (?), roe deer (?))	All warm-blooded animals including humans	Entzeroth et al. (1978); Mason (1978); Shimura and Ito (1986); Shimura and Ito (1987)
Experimental	Limited (rodents, goats, dogs, pigs, monkeys and rabbits but not birds)	All mammals and birds	Dubey (1975a); Frenkel and Dubey (1975); Wallace (1975); Dubey and Streitel (1976); Eydelloth (1977); Dubey and Wong (1978); Mason (1978); Dubey (1981a,b); Shimura and Ito (1986), Shimura and Ito (1987);
Tachyzoite infectivity (oral)	Absent	Present	Wallace (1975); Frenkel and Dubey (1975); Shimura and Ito (1986); Present study;
Bradyzoite infectivity (oral)	Absent	Present	Frenkel and Dueby (1975); Wallace (1975); Rommel and von Seyerl (1976); Mason (1978); Ogassawara et al. (1985); Shimura and Ito (1986); Present study
Tissue cyst location	Mainly extraneural	Mainly neural	Frenkel and Dubey (1975); Dubey and Streitel (1976); Present study
Congenital transmission	Absent	Present	Dubey and Streitel (1976)
In vitro cultivation			
Growth initiated by			
Sporozoites	Limited	Unlimited	Sheffield et al. (1976); Riahi et al. (1995); Present study
Tachyzoites	Limited	Unlimited	Present study
Bradyzoites	None	Unlimited	Present study
Morphologic			
Tachyzoites (μm)[a]	5.0 × 1.7 (4-6 × 1-2)	4.8 × 1-3 (4-6 × 1-2)	Present study
Rhoptries	Electron-dense	Electron-lucent	Sheffield et al. (1976); Present study
Bradyzoites (μm)[a]	5.9 × 1.3 (5-7 × 1-2)	5.4 × 1.1 (5-6.5 × 1-1.5)	Present study
Sporozoites (μm)[a]	6.3 × 1.3 (5-8 × 1-2)	5.6 × 1.0 (5-6.5 × 1-1.5)	Present study
Crystalloid body	Present	Absent	Sheffield et al. (1976)

[a] In Bouin's fixed, Giemsa-stained smears. Fifty specimens measured using identical conditions.

the fixative used. In the present study, this difference was consistent in spite of processing the two species by identical methods for TEM.

Sporozoites of *H. hammondi* are also structurally different from those of *T. gondii* because the crystalloid body present in sporozoites of *H. hammondi* and other coccidia is absent in *T. gondii* (Sheffield et al., 1976; Dubey et al., 1998; Speer et al., 1998). Mehlhorn and Heydorn (2000) and Heydorn and Mehlhorn (2001) regarded this difference to be related to fixation and embedding methods. However, the ultrastructure of *H. hammondi* and *T. gondii* sporozoites was studied under identical conditions (Sheffield et al., 1976; Speer et al., 1998).

There is no appreciable difference between tissue cysts and bradyzoites of *H. hammondi* and *T. gondii*. In the only report prior to the present study, Mehlhorn and Frenkel (1980) ultrastructurally compared the intramuscular cysts of *H. hammondi* and *T. gondii*. They reported differences in host parasite relationship with duration of *H. hammondi* infection, but not *T. gondii*. In tissue cysts from mice examined 35 day p.i., the tissue cyst wall of *H. hammondi* was surrounded by an electron-light zone which was absent in *T. gondii* tissue cysts. In the present study, *H. hammondi* tissue cysts were derived from mice fed oocysts 70 days earlier. In all four tissue cysts we examined, the primary tissue cyst wall was abutted directly against the myocyte cytoplasm. Mehlhorn and Frenkel (1980) also stated that *H. hammondi* bradyzoites (4–5 μm) were much smaller than those of *T. gondii* bradyzoites (7–8 μm), however, the number of bradyzoites they measured was not stated. Based on measurements of whole bradyzoites in stained smears in our study, *H. hammondi* bradyzoites were actually slightly bigger than those of *T. gondii* (Table 3). The localisation of *T. gondii* and *H. hammondi* tissue cysts differs in mice. Only a few *H. hammondi* tissue cysts are found in murine brains, and they are smaller in size compared with those in muscles of mice.

Hammondia hammondi has a limited host range in nature with cats as definitive hosts and rodents as intermediate hosts. This parasite has been isolated from faeces of naturally infected cats in the USA, Japan, and Germany (Frenkel and Dubey, 1975; Rommel and von Seyerl, 1976; Shimura and Ito, 1986). Mason (1978) reported that laboratory-raised cats fed tissues of naturally exposed rats and mice shed *H. hammondi* oocysts. Thus, rats and mice are natural intermediate hosts for *H. hammondi*. Although several other mammals have been experimentally infected with *H. hammondi* including primates, at present, rats, mice, and cats are the only known natural hosts. Experimental infections of pigeons, chickens and quails with *H. hammondi* were not successful (Frenkel and Dubey, 1975; Wallace, 1975; Dubey and Streitel, 1976).

The distinction of *H. hammondi* from *T. gondii* oocysts is epidemiologically important because *H. hammondi* is a parasite mainly of cats and rodents with no human or veterinary importance and because cats must be used for bioassay to isolate *T. gondii* from the tissues of food animals with low levels of infection (Dubey et al., 2002). The density of viable *T. gondii* in food animals is as low as one tissue cyst in 100 g of meat. As cats can shed millions of oocysts after ingesting as few as one bradyzoite (Dubey, 2001), the presence of even a few viable *T. gondii* in meat, which would be difficult to detect by conventional histology or by bioassay in mice, can be detected by bioassay in cats. However, the oocysts so obtained by this method must be bioassayed in mice and subpassaged from mouse to mouse to exclude *H. hammondi* infection.

There is no easy way to distinguish *H. hammondi* from *T. gondii* oocysts in cat faeces except by bioassay in mice. *Hammondia hammondi* cannot be maintained for more than one passage in mice whereas all strains of *T. gondii* can be maintained in mice indefinitely. It is difficult to detect concurrent *H. hammondi* and *T. gondii* oocysts in the same faecal sample and this may explain why there are only a few reports of natural *H. hammondi* infection. If oocysts from a combined infection are bioassayed in mice or cell culture, *T. gondii* would outgrow *H. hammondi*. Because it is difficult to obtain large numbers of *H. hammondi* for antigen preparation, there is no routine specific test to serologically distinguish these parasites in rodents. As stated earlier, *T. gondii* cross reacts with *H. hammondi* in a range of different serologic tests using *T. gondii* antigen. The level of cross reactivity varies with the serologic test, cut-off value, and the species of the animal tested (Frenkel and Dubey, 1975; Wallace, 1975; Rommel and von Seyerl, 1976; Christie and Dubey, 1977; Eydelloth, 1977; Weiland et al., 1979; Dubey, 1981a,b; Araujo et al., 1984; Linek, 1985; Munday and Dubey, 1986; Reddacliff et al., 1993; Riahi et al., 1998, 1999, 2001). However, this cross reactivity by itself is not enough to consider *H. hammondi* and *T. gondii* as the same parasite because cross reactivity has been documented between *Besnoitia jellisoni* and *T. gondii* that are relatively unrelated organisms (Lunde and Jacobs, 1965; Ruskin and Remington, 1968; Frenkel and Caldwell, 1975).

Unlike *T. gondii*, *H. hammondi* has an obligatory two-host cycle based on observations that the parasite is not transmitted congenitally, its oocysts and tachyzoites are not infective to the feline definitive host cat, and its tachyzoites and bradyzoites are not infective to rodent intermediate hosts (Table 3). Additionally, there is no extra-intestinal cycle of *H. hammondi* in cats, and tachyzoites and tissue cysts are not found in cats. In the present study, and that of Dubey (1975b), *H. hammondi* was not found in extra-intestinal tissues of cats, even when given massive doses of corticosteroids. Although in the present study cats were euthanised within 2 weeks of cortisone administration, in the study reported by Dubey (1975b) *H. hammondi*-infected cats were given a very high dose of cortisone (40 mg/kg/week) for several weeks before and after infection.

In addition to the results of the present study, the following are the counterpoints to the additional arguments raised by Heydorn and Mehlhorn (2001) regarding the validity of *H. hammondi*:

(a) In their opinion only a few cats and isolates of *H. hammondi* were used; cats used were of uncertain origin, and the research was performed in few laboratories, and many years ago. In fact, the cats used by Dubey (1975a,b), Christie et al. (1977), and in the present study, were all derived from a closed colony that was started in Columbus, OH in 1965 (Dubey, 1995). These cats and their ancestors had been fed only processed dry cat food before use in experiments, thus they were free of *H. hammondi* or *T. gondii* before use in experiments. Spontaneous *T. gondii*-like oocysts have never been found in hundreds of cats from this colony. According to Heydorn and Mehlhorn (2001) there were not enough data to prove non-infectivity of oocysts of *H. hammondi* to cats because only 26 cats were used (Wallace, 1973; Christie et al., 1977; Mason, 1978; Shimura and Ito, 1986). This point was not investigated further because there is a limit to pursuing a negative finding. Heydorn and Mehlhorn (2001) also cited two rare findings to promote their argument. In two experiments, cats fed intestinal tissues of *H. hammondi*-infected cats shed *H. hammondi* oocysts (Frenkel and Dubey, 1975; Christie et al., 1977); these findings from the literature were interpreted by Heydorn and Mehlhorn (2001) to suggest that bradyzoites might be present in cats. However, it is not known whether schizonts or gamonts or both remain trapped in the intestine of chronically *H. hammondi*-infected cats, and occasionally initiate reshedding of oocysts. The original isolate of *H. hammondi* was obtained from a naturally infected cat that shed oocysts after cortisone administration (Dubey and Frenkel, 1974; Frenkel and Dubey, 1975).
(b) They cited rare findings from literature to question the non-infectivity of *H. hammondi* tachyzoites and bradyzoites to mice. They argued that Shimura and Ito (1986) found a tissue cyst in an abdominal muscle of a mouse inoculated with tachyzoites of *H. hammondi* and that Wallace (1975) reported that homogenates of viscera of mice inoculated with excysted sporozoites were infective to mice. Whether sporozoites survived in the peritoneum is uncertain. In the same paper, Wallace (1975) reported another exception; in one case *H. hammondi* bradyzoites were infective to a cortisone-treated mouse. However, in all the above instances, *H. hammondi* was not transmitted by a second passage from mouse to mouse. In the present study organisms obtained from the mesenteric lymph nodes of mice that had been fed oocysts 1 and 4 days earlier, were infective to other mice by subpassage. It may be that not all sporozoites convert to tachyzoites in mice fed oocysts by 4 days p.i. and this may account for these rare infections. The number of multiplicative cycles of tachyzoites before transformation to bradyzoites has not been determined and may also affect subinoculation results. Thus, we conclude that *H. hammondi* tachyzoites and bradyzoites are not infective to intermediate hosts except in certain circumstances just stated. This is an important conclusion because hundreds of *T. gondii* isolates have been routinely maintained in many laboratories by mouse to mouse passage.
(c) They dismissed the molecular and antigenic differences between *H. hammondi* and *T. gondii* summarised by Frenkel and Dubey (2000) and dwelled on similarity of preliminary findings on G + C content of *T. gondii* and *H. hammondi* reported by Johnson et al. (1987) when molecular techniques were primitive. The differences in full-length large subunit ribosomal RNA gene and internal transcribed spacer (ITS)-1 sequences (Ellis et al., 1999; Jenkins et al., 1999; Mugridge et al., 1999) and isoenzymes (Dardé et al., 1992) among *H. hammondi* and *T. gondii* are far greater than found among isolates of *T. gondii*. For example, Homan et al. (1997) found that the ITS-1 sequences of 20 isolates of *T. gondii* were identical, independent of their origin and virulence to mice. Recently, Su et al. (2003) also observed that there was complete homology of the ITS-1 sequence among isolates of *T. gondii* from all clonal lineages. However, comparison of a 413 bp stretch of ITS- 1 (Ellis et al., 1999) of *T. gondii* (Genbank No. AF49390) and *H. hammondi* (AF 076857) revealed a 3.8% difference (16 bp) in the nucleotide sequence.

Heydorn and Mehlhorn (2001) stated that there were only minor differences in tissue cysts of *H. hammondi* and *T. gondii*. We agree with their conclusion. In *T. gondii* infection, tissue cysts occur principally in the brain of mice but also in many other tissues including muscles, whereas in *H. hammondi* infection tissue cysts are found primarily in muscles and rarely in the brain. However, this difference alone should not be used to distinguish these parasites because tissue cysts of *H. hammondi* do occur in the brain and there is no structural difference between their tissue cysts.

Acknowledgements

We would like to thank John Jenkins, AFIP, Washington, DC and Kathy Kuehl, USAMRIID, Fort Detrick, Maryland for electron micrographs, and Drs. D. Fritz, J.K. Frenkel, H.R. Gamble, D.E. Hill, M.C. Jenkins, R. Lichtenfels, and B.M. Rosenthal for their assistance in the preparation of the manuscript.

References

Araujo, F.G., Dubey, J.P., Remington, J.S., 1984. Antigenic similarity between the coccidian parasites *Toxoplasma gondii* and *Hammondia hammondi*. J. Protozool. 31, 145–147.

Christie, E., Dubey, J.P., 1977. Cross-immunity between *Hammondia* and *Toxoplasma* infections in mice and hamsters. Infect. Immun. 18, 412–415.

Christie, E., Dubey, J.P., Pappas, P.W., 1977. Prevalence of *Hammondia hammondi* in feces of cats in Ohio. J. Parasitol. 63, 929–931.

Dardé, M.L., Riahi, H., Bouteille, B., Pestre-Alexandre, M., 1992. Isoenzyme analysis of *Hammondia hammondi* and *Toxoplasma gondii* sporozoites. J. Parasitol. 78, 731–734.

Dubey, J.P., 1975a. Experimental *Hammondia hammondi* infection in dogs. Br. Vet. J. 131, 741–743.

Dubey, J.P., 1975b. Immunity to *Hammondia hammondi* infection in cats. J. Am. Vet. Med. Assoc. 167, 373–377.

Dubey, J.P., 1981a. Prevention of abortion and neonatal death due to toxoplasmosis by vaccination of goats with the nonpathogenic coccidium *Hammondia hammondi*. Am. J. Vet. Res. 42, 2155–2157.

Dubey, J.P., 1981b. Protective immunity against clinical toxoplasmosis in dairy goats vaccinated with *Hammondia hammondi* and *Hammondia heydorni*. Am. J. Vet. Res. 42, 2068–2070.

Dubey, J.P., 1995. Duration of immunity to shedding of *Toxoplasma gondii* oocysts by cats. J. Parasitol. 81, 410–415.

Dubey, J.P., 2001. Oocyst shedding by cats fed isolated bradyzoites and comparison of infectivity of bradyzoites of the VEG strain *Toxoplasma gondii* to cats and mice. J. Parasitol. 87, 215–219.

Dubey, J.P., Beattie, C.P., 1988. Toxoplasmosis of Animals and Man. CRC Press, Boca Raton, FL.

Dubey, J.P., Desmonts, G., 1987. Serological responses of equids fed *Toxoplasma gondii* oocysts. Equine Vet. J. 19, 337–339.

Dubey, J.P., Frenkel, J.K., 1972. Cyst-induced toxoplasmosis in cats. J. Protozool. 19, 155–177.

Dubey, J.P., Frenkel, J.K., 1974. Immunity to feline toxoplasmosis: modification by administration of corticosteroids. Vet. Pathol. 11, 350–379.

Dubey, J.P., Lindsay, D.S., 1998. Isolation in immunodeficient mice of *Sarcocystis neurona* from opossum (*Didelphis virginiana*) faeces, and its differentiation from *Sarcocystis falcatula*. Int. J. Parasitol. 28, 1823–1828.

Dubey, J.P., Streitel, R.H., 1976. Further studies on the transmission of *Hammondia hammondi* in cats. J. Parasitol. 62, 548–551.

Dubey, J.P., Wong, M.M., 1978. Experimental *Hammondia hammondi* infection in monkeys. J. Parasitol. 64, 551–552.

Dubey, J.P., Lunney, S.K., Shen, S.K., Kwok, O.C.H., Ashford, D.A., Thulliez, P., 1996. Infectivity of low numbers of *Toxoplasma gondii* oocysts to pigs. J. Parasitol. 82, 438–443.

Dubey, J.P., Lindsay, D.S., Speer, C.A., 1998. Structure of *Toxoplasma gondii* tachyzoites, bradyzoites and sporozoites, and biology and development of tissue cysts. Clin. Microbiol. Rev. 11, 267–299.

Dubey, J.P., Mattson, D.E., Speer, C.A., Baker, R.J., Mulrooney, D.M., Tornquist, S.J., Hamir, A.N., Gerros, T.C., 1999. Characterization of *Sarcocystis neurona* isolate (SN6) from a naturally infected horse from Oregon. J. Eukaryot. Microbiol. 46, 500–506.

Dubey, J.P., Gamble, H.R., Hill, D., Sreekumar, C., Romand, S., Thulliez, P., 2002. High prevalence of viable *Toxoplasma gondii* infection in market weight pigs from a farm in Massachusetts. J. Parasitol. 88, 1234–1238.

Ellis, J.T., Morrison, D.A., Liddell, S., Jenkins, M.C., Mohammed, O.B., Ryce, C., Dubey, J.P., 1999. The genus *Hammondia* is paraphyletic. Parasitology 118, 357–362.

Entzeroth, R., Scholtyseck, E., Greuel, E., 1978. The roe deer intermediate host of different coccidia. Naturwissenschaften 65, 395.

Eydelloth, M., 1977. Experimentelle untersuchungen über das wirtsspektrum von *Hammondia hammondi*, Thesis, Munich, Germany, pp. 1–46.

Frenkel, J.K., Caldwell, S.A., 1975. Specific immunity and nonspecific resistance to infection: *Listeria*, protozoa, and viruses in mice and hamsters. J. Infect. Dis. 131, 201–209.

Frenkel, J.K., Dubey, J.P., 1975. *Hammondia hammondi* gen nov., sp.nov., from domestic cats, a new coccidian related to *Toxoplasma* and *Sarcocystis*. Zeits. Parasitenk. 46, 3–12.

Frenkel, J.K., Dubey, J.P., 2000. The taxonomic importance of obligate heteroxeny: distinction of *Hammondia hammondi* from *Toxoplasma gondii*—another opinion. Parasitol. Res. 86, 783–786.

Heydorn, A.O., Mehlhorn, H., 2001. Further remarks on *Hammondia hammondi* and the taxonomic importance of obligate heteroxeny. Parasitol. Res. 87, 573–577.

Homan, W.L., Limper, Verlaan, L.M., Borst, A., Vercammen, M., van Knapen, F., 1997. Comparison of the internal transcribed spacer ITS 1, from *Toxoplasma gondii* isolates and *Neospora caninum*. Parasitol. Res. 83, 285–289.

Jenkins, M.C., Ellis, J.T., Liddell, S., Ryce, C., Munday, B.L., Morrison, D.A., Dubey, J.P., 1999. The relationship of *Hammondia hammondi* and *Sarcocystis mucosa* to other heteroxenous cyst-forming coccidia as inferred by phylogenetic analysis of the 18S SSU ribosomal DNA sequence. Parasitology 119, 135–142.

Johnson, A.M., Illana, S., Dubey, J.P., Dame, J.B., 1987. *Toxoplasma gondii* and *Hammondia hammondi*: DNA comparison using cloned rRNA gene probes. Exp. Parasitol. 63, 272–278.

Karnovsky, M.J.A., 1965. A formaldehyde–glutaraldehyde fixative of high osmolality for use in electron microscopy. J. Cell. Biol. 27, 137A.

Linek, M., 1985. Verlauf der Antikörpertiter im Serum von Katzen nach experimenteller infektion mit *Toxoplasma gondii* und *Hammondia hammondi*, D.V.M. thesis, Tierärztliche Hochschule Hannover, Germany, pp. 1–49.

Lunde, M.N., Jacobs, L., 1965. Antigenic relationship of *Toxoplasma gondii* and *Besnoitia jellisoni*. J. Parasitol. 51, 273–276.

Mason, R.W., 1978. The detection of *Hammondia hammondi* in Australia and the identification of a free-living intermediate host. Zeits. Parasitenk. 57, 101–106.

McAllister, M.M., Parmley, S.F., Weiss, L.M., Welch, V.J., McGuire, A.M., 1996. An immunohistochemical method for detecting bradyzoite antigen (BAG5) in *Toxoplasma gondii*-infected tissues cross-reacts with a *Neospora caninum* bradyzoite antigen. J. Parasitol. 82, 354–355.

Mehlhorn, H., Frenkel, J.K., 1980. Ultrastructural comparison of cysts and zoites of *Toxoplasma gondii*, *Sarcocystsis muris*, and *Hammondia hammondi* in skeletal muscle of mice. J. Parasitol. 66, 59–67.

Mehlhorn, H., Heydorn, A.O., 2000. *Neospora caninum*: is it really differently from *Hammondia heydorni* or is it a strain of *Toxoplasma gondii*? An opinion. Parasitol. Res. 86, 169–178.

Mugridge, .B., Morrison, D.A., Heckeroth, A.R., Johnson, A.M., Tenter, A.M., 1999. Phylogenetic analysis based on full-length large subunit ribosomal RNA gene sequence comparison reveals that *Neospora caninum* is more closely related to *Hammondia heydorni* than to *Toxoplasma gondii*. Int. J. Parasitol. 29, 1545–1556.

Munday, B.L., Dubey, J.P., 1986. Serological cross-reactivity between *Hammondia hammondi* and *Toxoplasma gondii* in experimentally inoculated sheep. Aust.Vet. J. 63, 344–345.

Ogassawara, S., Jamra, L.M.F., Leme, P.T.Z., Hagiwara, M.R., 1985. *Hammondia hammondi* nas fezes de gatos na cidode de São Paulo, Brazil. Rev. Microbiol. São Paulo 16, 36–40.

Reddacliff, G.L., Parker, S.J., Dubey, J.P., Nicholls, P.J., Johnson, A.M., Cooper, D.W., 1993. An attempt to prevent acute toxoplasmosis in macropods by vaccination with *Hammondia hammondi*. Aust.Vet. J. 70, 33–35.

Riahi, H., Dardé, M.L., Bouteille, B., Leboutet, M.J., Pestre-Alexandre, M., 1995. *Hammondia hammondi* cysts in cell cultures. J. Parasitol. 81, 821–824.

Riahi, H., Bouteille, B., Dardé, M.L., 1998. Antigenic similarity between *Hammondia hammondi* and *Toxoplasma gondii* tachyzoites. J. Parasitol. 84, 651–653.

Riahi, H., Leboutet, M.J., Bouteille, B., Dubremetz, J.F., Dardé, M.L., 1999. *Hammondia hammondi* organelle proteins are recognized by

monoclonal antibodies directed against organelles of *Toxoplasma gondii*. J. Parasitol. 85, 580–583.

Riahi, H., Leboutet, M.J., Labrousse, J., Bouteille, B., Dardé, M.L., 2001. Monoclonal antibodies to *Hammondia hammondi* allowing an immunological differentiation from *Toxoplasma gondii*. J. Parasitol. 86, 1362–1366.

Rommel, M., von Seyerl, F., 1976. Der erstmalige nachweis von *Hammondia hammondi* (Frenkel und Dubey 1975) im kot einer katze in Deutschland. Berl. Münch. Tierärztl. Wochenschr. 89, 398–399.

Ruskin, J., Remington, J.S., 1968. Role for the macrophage in acquired immunity to phylogenetically unrelated intracellular organisms. Antimicrob. Agents Chemother. 8, 474–477.

Sheffield, H.G., Melton, M.L., Neva, F.A., 1976. Development of *Hammondia hammondi* in cell cultures. Proc. Helminthol. Soc. Wash. 43, 217–225.

Shimura, K., Ito, S., 1986. Isolation of *Hammondia hammondi* in Japan. Jpn. J. Vet. Sci. 48, 901–908.

Shimura, K., Ito, S., 1987. Goats as natural intermediate hosts of *Hammondia hammondi*. Zbl. Bakt. Hyg. 264, 348–352.

Speer, C.A., Clark, S., Dubey, J.P., 1998. Ultrastructure of the oocysts, sporocysts and sporozoites of *Toxoplasma gondii*. J. Parasitol. 84, 505–512.

Su, C., Evans, D., Cole, R.H., Kissinger, J.C., Ajioka, J.W., Sibley, L.D., 2003. Recent expansion of *Toxoplasma* through enhanced oral transmission. Science 299, 414–416.

Tenter, A.M., Heckeroth, A.R., Weiss, L.M., 2000. *Toxoplasma gondii*: from animals to humans. Int. J. Parasitol. 30, 1217–1258.

Wallace, G.D., 1973. *Sarcocystis* in mice inoculated with *Toxoplasma*-like oocysts from cat feces. Science 180, 1375–1377.

Wallace, G.D., 1975. Observations on a feline coccidium with some characteristics of *Toxoplasma* and *Sarcocystis*. Zeits. Parasitenk. 46, 167–178.

Weiland, G., Rommel, M., Von Seyerl, F., 1979. Serological cross-reactions between *Toxoplasma* and *Hammondia*. Zbl. Bakt. Hyg., I. Abt. Orig. A 244, 391–393.