Available online at www.sciencedirect.com
SCIENCE DIRECT®
ELSEVIER
International Journal for Parasitology 34 (2004) 1157–1167
www.parasitology-online.com

Biologic, morphologic, and molecular characterisation of *Neospora caninum* isolates from littermate dogs☆

J.P. Dubey[a,*], C. Sreekumar[a], E. Knickman[b], K.B. Miska[a], M.C.B. Vianna[a], O.C.H. Kwok[a], D.E. Hill[a], M.C. Jenkins[a], D.S. Lindsay[c], C.E. Greene[d]

[a]*US Department of Agriculture, Agricultural Research Service, Animal and Natural Resources Institute, Animal Parasitic Diseases Laboratory, BARC-East, Building 1040, 10300 Baltimore Avenue, Beltsville, MD 20705-2350, USA*
[b]*Madonna Veterinary Clinic, 4105 Norrisville road, White Hall, MD 21161, USA*
[c]*Department of Biomedical Sciences and Pathobiology, Center for Molecular Medicine and Infectious Diseases, Virginia-Maryland Regional College of Veterinary Medicine, Virginia Tech, 1410 Prices Fork Road, Blacksburg, VA 24061-0342, USA*
[d]*Department of Small Animal Medicine, College of Veterinary Medicine, The University of Georgia, Athens, GA 30602, USA*

Received 23 April 2004; received in revised form 8 July 2004; accepted 8 July 2004

Abstract

Isolation and biologic and molecular attributes of *Neospora caninum* from three littermate dogs are described. Tissue cysts were confined to the brain and striated muscles. *N. caninum* was isolated (isolates NC-6, NC-7, and NC-8) in rodents and cell culture that had been inoculated with brain tissue from the dogs. Schizont-like stages reactive with *N. caninum* antibodies were seen in cell cultures seeded with bradyzoites released from Percoll-isolated *N. caninum* tissue cysts from the brain of one dog. Tissue cysts were infective orally to mice and gerbils, but not to cats and dogs. The isolates were also identified as *N. caninum* by PCR and sequence analysis.
© 2004 Australian Society for Parasitology Inc. Published by Elsevier Ltd. All rights reserved.

Keywords: Neosporosis; *Neospora caninum*; Isolation; Mice; Gerbils; Cell culture; Bradyzoites; Ultrastructure; Sequence analysis; Schizogony

1. Introduction

Neosporosis is now recognised as an important cause of morbidity and mortality in dogs throughout the world (reviewed by Dubey and Lindsay, 1996; Dubey, 2003). Little is known of biologic characters of *Neospora caninum* isolates from dogs. In the present paper, we report isolation of *N. caninum* in cell culture, gerbils and mice, transmission to other animals, and describe structure of the tissue cysts and bradyzoites from three littermate dogs. We also report the development of schizont-like stages of *N. caninum* in cell culture for the first time.

2. Materials and methods

2.1. Naturally-infected dogs

Neosporosis was suspected ante-mortem in three of 11 pups born from a 5-year-old Labrador bitch. The dogs (No. 1–3) were donated to the USDA because they were paralysed in spite of a 6-week treatment with clindamycin. Two dogs were euthanised when 116 day old and necropsied immediately. The third dog was euthanised when 135 day old; its carcass was refrigerated for three days before necropsy examination.

The naturally-infected dogs and experimental animals were cared for in accordance with the US Department of Agriculture approved Animal Care Guidelines.

2.2. Necropsy examination of dogs and collection of materials for bioassays

Complete necropsy examinations were performed on all three dogs. The entire brain and spinal cords were removed.

☆ Nucleotide sequence data reported in this paper are available in the GenBank, EMBL and DDBJ databases under the accession numbers: AY665720, AY665721, AY665722, AY665719.

* Corresponding author. Tel: +1-301-504-8128; fax: +1-301-504-9222.
E-mail address: jdubey@anri.barc.usda.gov (J.P. Dubey).

0020-7519/$30.00 © 2004 Australian Society for Parasitology Inc. Published by Elsevier Ltd. All rights reserved.
doi:10.1016/j.ijpara.2004.07.005

Specimens of cerebrum, cerebellum, pons, medulla, cervical, thoracic, and lumbar spinal cords, tongue, heart, lung, liver, adrenals, spleen, kidneys, eyes, sciatic nerve, oesophagus, stomach, intestines, and muscles from masseter, diaphragm and limbs were fixed in buffered neutral 10% formalin. For direct microscopic examination, 2–3 mm pieces of the cerebrum of dogs were crushed on glass slides under cover slip, and examined microscopically for tissue cysts. To free tissue cysts from the brain material, small pieces of cerebrum were homogenised in phosphate buffer saline (PBS) and centrifuged in Percoll as described (McGuire et al., 1997). Tissue cysts were washed free of Percoll (Pharmacia/ Upjohn) and used for cultivation within 1 h of washing.

2.3. Attempted isolation of *N. caninum* from dogs in cell culture and rodents

For isolation of *N. caninum* in cell culture, approximately 5 g of brain tissue from dog no. 1 was homogenised in Hank's balanced salt solution (HBSS) and inoculated on to M 617 cell monolayers without any further treatment. From dog nos. 2 and 3, 20 g of brain and spinal cord were homogenised in 250 ml HBSS and 10 ml of the homogenate were used to inoculate cell cultures without further treatment. To the rest of the homogenate 250 ml of 0.5% trypsin solution was added, and the mixture was incubated for 30 min at 37 °C, centrifuged, washed three times with HBSS, and then inoculated on to M617 cells in a tissue culture flask as described by Dubey et al. (1998). After 1 h incubation, the inoculum was removed, rinsed with plain medium and replaced with fresh growth medium.

Monolayers of CV1 cells were also inoculated with lung tissue extracts of interferon-gamma gene knockout mice (KO) mice that had been previously infected with brain homogenate from dog no. 1.

The development of *N. caninum* in cell cultures was studied after inoculation with bradyzoites. Tissue cysts from the brain of dog no. 1 were purified over Percoll. The tissue cyst pellet was treated with acid pepsin solution (Dubey, 1998) to facilitate release of the bradyzoites. The washed suspension was layered over CV1 monolayers grown on seven 12 mm cover slips in multi-well plates (Dubey and Sreekumar, 2003). Cover slips were removed at 15, 40, 64, 98,140, and 168 h, fixed with Bouin's and stained with Giemsa. The cover slips removed at 64 and 98 h and stained with Giemsa were subsequently destained and reacted immunohistochemically with *N. caninum* polyclonal rabbit antibodies (see Section 2.6).

For isolation in animals, brain tissues from dog nos. 1 to 3 were inoculated into KO mice, gerbils, or both (Table 1). Trypsin digested brain (used for cell culture) from dog no. 3 was inoculated s.c. into KO mice, gerbils, and Swiss Webster (SW) out-bred albino mice (Table 1). Additionally, homogenised but undigested brain was inoculated s.c. into KO mice. From dog no. 1, a small piece of brain was crushed between a cover slip and slide and after confirming the presence of protozoal tissues cysts, the cover slip was removed and the brain tissue was washed off the slide using HBSS. The brain suspension containing tissue cysts was inoculated s.c. into three KO mice (Table 1).

2.4. Serological examination

Sera from animals were examined for antibodies to *N. caninum* using direct *Neospora* agglutination test (NAT, Romand et al., 1998) and for antibodies to *Toxoplasma gondii* using the modified agglutination test (MAT) as described (Dubey and Desmonts, 1987).

Table 1
Infectivity of *Neospora caninum* isolates to rodents

Source of inoculum	Animal species	No.	Inoculum	Route	Outcome[a] days p.i.	*N. caninum* found
NC-6 (Dog 1)	KO mice	3	Undigested dog brain	s.c.	D 27	Tachyzoites
	KO mice	4	Cell culture[b]	s.c.	D 7–11	Tachyzoites
	Gerbils	5	Cell culture[b]	s.c.	D 9–11	Tachyzoites
NC-7 (Dog 2)	KO mice	5	Digested dog brain	s.c.	D 11–16	Tachyzoites
	KO mice	2	Undigested dog brain	s.c.	D 12,16	Tachyzoites
	KO mice	5	Undigested dog brain	Oral	D 20–23	Tachyzoites
	KO mice	2	Cell culture[b]	s.c.	D 11	Tachyzoites
	SW mice	5	Digested dog brain	s.c.	S 60	No[c]
	Gerbils	2	Digested dog brain	s.c.	S 60	No[c]
NC-8 (Dog 3)	KO mice	5	Digested dog brain	s.c.	D 14–17	Tachyzoites
	KO mice	2	Digested dog brain	s.c.	D 19,20	Tachyzoites
	KO mice	5	Undigested dog brain	Oral	D 23–28	Tachyzoites
	KO mice	2	Cell culture[b]	s.c.	D 16–19	Tachyzoites
	SW mice	5	Dog brain	s.c.	S 60	No[c]
	Gerbils	3	Digested dog brain	s.c.	S 73	Tissue cysts

[a] D = died or killed when ill. S = survived, not ill.
[b] Supernatant medium from infected CV1 cultures.
[c] Developed *N. caninum* antibodies (NAT 1: 160 or more).

2.5. Examination of mice inoculated with canine tissues

Rodents inoculated with canine tissues were examined for *N. caninum* and *T. gondii* parasites. Impression smears of lungs and brain of mice that died were fixed in methanol and examined after staining with Giemsa. Survivors were bled 6–8 weeks p.i. and 1:25 dilutions of their sera were examined for *T. gondii* antibodies by MAT and *N. caninum* antibodies by NAT.

2.6. Histological and immunohistochemical examination and transmission electron microscopy (TEM)

For histologic examination, paraffin embedded sections were cut at 5–6 μm thickness and examined after staining with H and E. For immunohistochemical examination, a Dako Envision Peroxidase (Dako, Carpinteria, CA) rabbit kit and Envision system was used. Deparaffinised sections were stained with polyclonal rabbit anti-*N. caninum* or *T. gondii* antibodies (Lindsay and Dubey, 1989a; Dubey et al., 2001), and polyclonal rabbit recombinant BAG (bradyzoite antigen)-1 antibodies (McAllister et al., 1996b). Giemsa stained cover slips of infected CV1 monolayers were destained and examined after immunostaining. For this, the cover slips were destained with 1% acid alcohol and stained with anti-*N. caninum* antibodies using a *N. caninum* infected monolayer as a positive control and *T. gondii* infected monolayers as negative control (Dubey and Sreekumar, 2003).

For TEM examination, samples of brain were fixed in Karnovsky fixative, post-fixed in 1% (w/v) osmium tetroxide and prepared for TEM. Tissue cysts from dog no. 1 were also purified using Percoll and the pellet was used for TEM studies.

2.7. Molecular characterisation

The three *N. caninum* isolates from littermate dogs in the present study were compared with the type strain (NC-Original, see below) of *N. caninum*. DNA was extracted from *N. caninum* infected tissues as described (Sreekumar et al., 2003). PCR was performed with the *N. caninum*-specific primers Np6-Np21 amplifying a portion of the gene5 region (Yamage et al., 1996) and common *Toxoplasma* group ITS-1 primers (Sreekumar et al., 2003), including positive (NC-Original) and negative controls. The PCR products were electrophoresed on a 1.5% agarose gel and observed for the presence specific target fragment. The specific PCR product was gel cleaned and directly sequenced in both directions using the Big Dye terminator system, version e 3.1 (Applied Biosystems, Foster City, CA) using an ABI 377 sequencer. The sequence chromatograms were edited using Sequencher 4.1 software (Genecodes Corp., Ann Arbor, MI). To rule out the presence of *T. gondii* and *Hammondia heydorni*, PCR assays were performed with primers amplifying the SAG1 region specific to *T. gondii* (Sibley and Boothroyd, 1992) and ITS-1 region specific to *H. heydorni* (Šlapeta et al., 2002).

The NC-1 strain was originally isolated in cell culture inoculated with neural tissues of a dog in 1988 (Dubey et al., 1988, 2002). Since then, this isolate has been used widely for neosporosis research and has been maintained in cell culture in many laboratories. It is not known whether this prolonged cultivation has changed its genetic or biological characteristics. Therefore, we attempted to revive the isolate after 12 years in liquid nitrogen. The NC-1 isolate was cryopreserved in liquid nitrogen on 31 March 1988. A vial was revived and contents were inoculated into KO mice; organisms from one of the KO mice were used to infect cell culture. Tachyzoites from culture (named as NC-Original) were used for DNA extraction.

2.8. Viability of N. caninum tissue cysts stored at 4 °C

Brain tissue from dog no. 3 that was stored for 10 and 31 days, and from dog no. 1 stored for 7 and 23 days were inoculated s.c. in to two to five KO mice to test for viability (see Table 1).

2.9. Bioassay in dogs and cats

About 50 g of brain tissue and 2 kg of muscle from carcasses of dog nos. 2 and 3 were fed to each of four laboratory-raised beagles obtained from Covance Research Products, Cumberland, VA, USA and to two hound breed dogs obtained from Covance Research Inc., Denver, PA, USA. In addition, about 25 g of brain and about 250 g of muscle from dog nos. 2 and 3 were fed to two laboratory raised cats from the USDA laboratory as described (Dubey, 1995). Infected tissues from dog nos. 2 and 3 were fed to experimental dogs and cats on the same day the dogs were necropsied. The dogs and cats had never been fed uncooked meat prior to the present experiment. All animals were maintained in vermin-proof enclosures.

Faeces of dogs and cats were examined daily for coccidian oocysts from day 3 to 30 post-feeding of canine tissues. The beagles were euthanised 31, 42, 42, and 62 days p.i. and the hounds were euthanised 17 days p.i. The cats were euthanised 35 days p.i.

2.10. Cytological study of bradyzoites

For study of bradyzoites, tissue cysts were isolated from brain tissue of dog no. 2 on a Percoll gradient, washed, microisolated, and two individual tissue cysts were placed on two glass slides. Bradyzoites were released mechanically, air dried, fixed in Bouins, and stained with Giemsa. Bradyzoites (68 from one, and 32 from the second tissue cyst) were measured using the motorised system microscope (Olympus Optical Co., Tokyo, Japan) with an Olympus FV camera and Olympus Microsuite™ B3SV computer program.

3. Results

3.1. Tissue cysts and bradyzoites

Tissue cysts (Fig. 1A–D) were unevenly distributed in canine tissues. In numerous (>50) squash preparations of 2–3 mm^3 samples of brain of all three dogs, some preparations had up to 12 tissue cysts whereas the majority had none. In preparations of brain homogenised in saline, the largest tissue cyst was 65 μm in diameter, it contained numerous bradyzoites enclosed in a 4.5 μm thick cyst wall (Fig. 1A); the smallest tissue cyst found was 14 μm in diameter and it contained approximately 15 bradyzoites enclosed in a well-defined tissue cyst wall, whose thickness was ~1 μm (Fig. 1D).

In Giemsa stained smears, bradyzoites were curved with the nucleus often located at the narrower end (Fig. 1E). A diffusely stained area was visible at the broader end and probably represented the area where micronemes were present (Fig. 1E). The bradyzoites released from one tissue cyst were 6.5×1.4 μm (4.8–8.0×1.0–1.9, $n=68$) and from the second tissue cyst were 6.6×1.7 μm (5.6–7.1×1.3–2.3, $n=32$). Overall bradyzoites from two tissue cysts averaged 6.5×1.5 μm in size.

Fourteen tissue cysts were examined ultrastructurally. Two tissue cysts were from the unhomogenised brain and 12 tissue cysts were from the Percoll-floated material. The tissue cyst walls were often wavy or irregular in outline with a thickness of 0.7–2.4 μm within the same tissue cyst. (Figs. 2 and 3). The tissue cyst wall contained amorphous material with electron-dense and electron-lucent vacuoles (Fig. 2B). Bradyzoites were juxtaposed with the tissue cyst wall (Fig. 2). Longitudinally cut bradyzoites ($n=12$) were 4.5–7.9×1.4–1.8 μm in size. Intact bradyzoites had a conoid, numerous micronemes, rhoptries, amylopectin, and a nucleus. A membrane-bound body was located towards the conoidal end (Fig. 2B). There were numerous micronemes, which were concentrated in the anterior (conoidal) one-third of the bradyzoites, but a few were present posterior to the nucleus. The micronemes were not arranged in any definite pattern. They were approximately 232×58 nm in size. The rhoptries extended throughout the length of the bradyzoite. The contents of the rhoptries were electron-dense and the bulbous end of the rhoptries was up to 145 nm wide. Amylopectin granules were located mostly in the middle third of the bradyzoite. The nucleus was often terminal (Fig. 2). A micropore was sometimes visible towards the conoidal end. The thickness of the bradyzoites varied from 1.2 to 1.8 μm. Some bradyzoites were wider at the conoidal end, whereas others were wider towards the nuclear end (Fig. 3). Several bradyzoites in intact tissue cysts were degenerating (Figs. 2A and 3).

N. caninum tissue cysts were confined to the brain and the muscles; tachyzoites were not seen. The distribution of tissue cysts in tissues was sporadic. Intact, degenerating, and ruptured tissue cysts were seen (Fig. 4A–D). A few intact tissue cysts were present in neural tissue without any

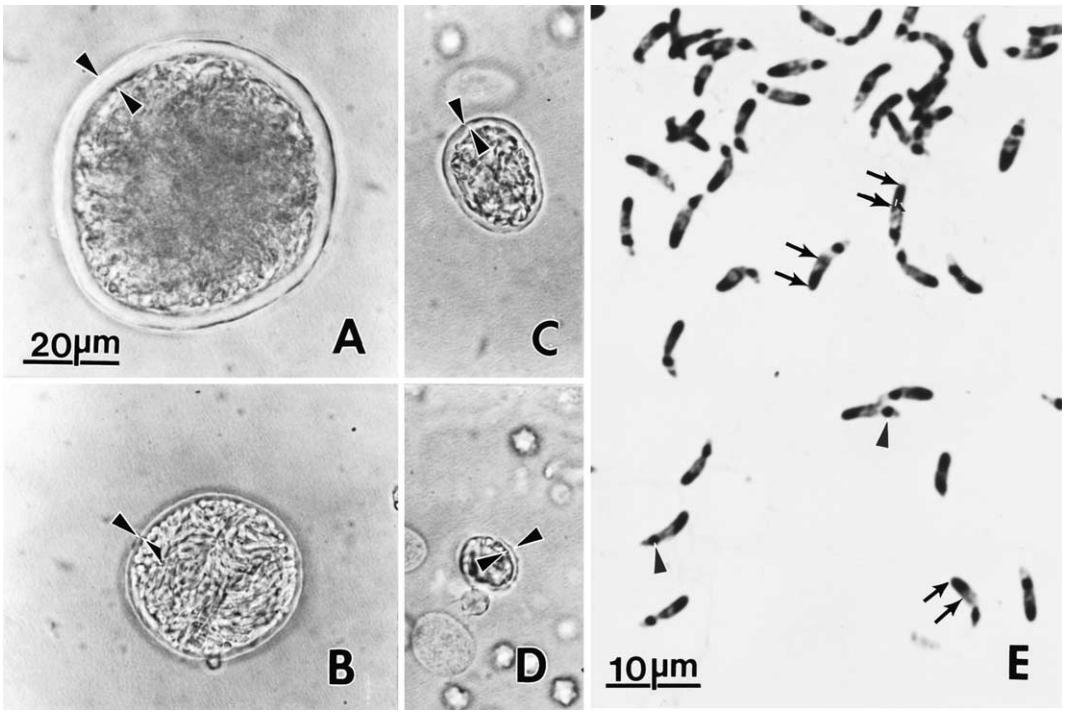

Fig. 1. Tissue cysts and bradyzoites of *Neospora caninum* in smears of brain homogenate from dog no. 3. (A–D) Tissue cysts of different sizes with cyst walls of varying thickness (opposing arrowheads). Unstained. (E) Bradyzoites released from a tissue cyst. Note the location of the nucleus (arrowheads) at the narrow non-conoidal end, and a dark staining area (arrows) at the broader conoidal end. Giemsa stain.

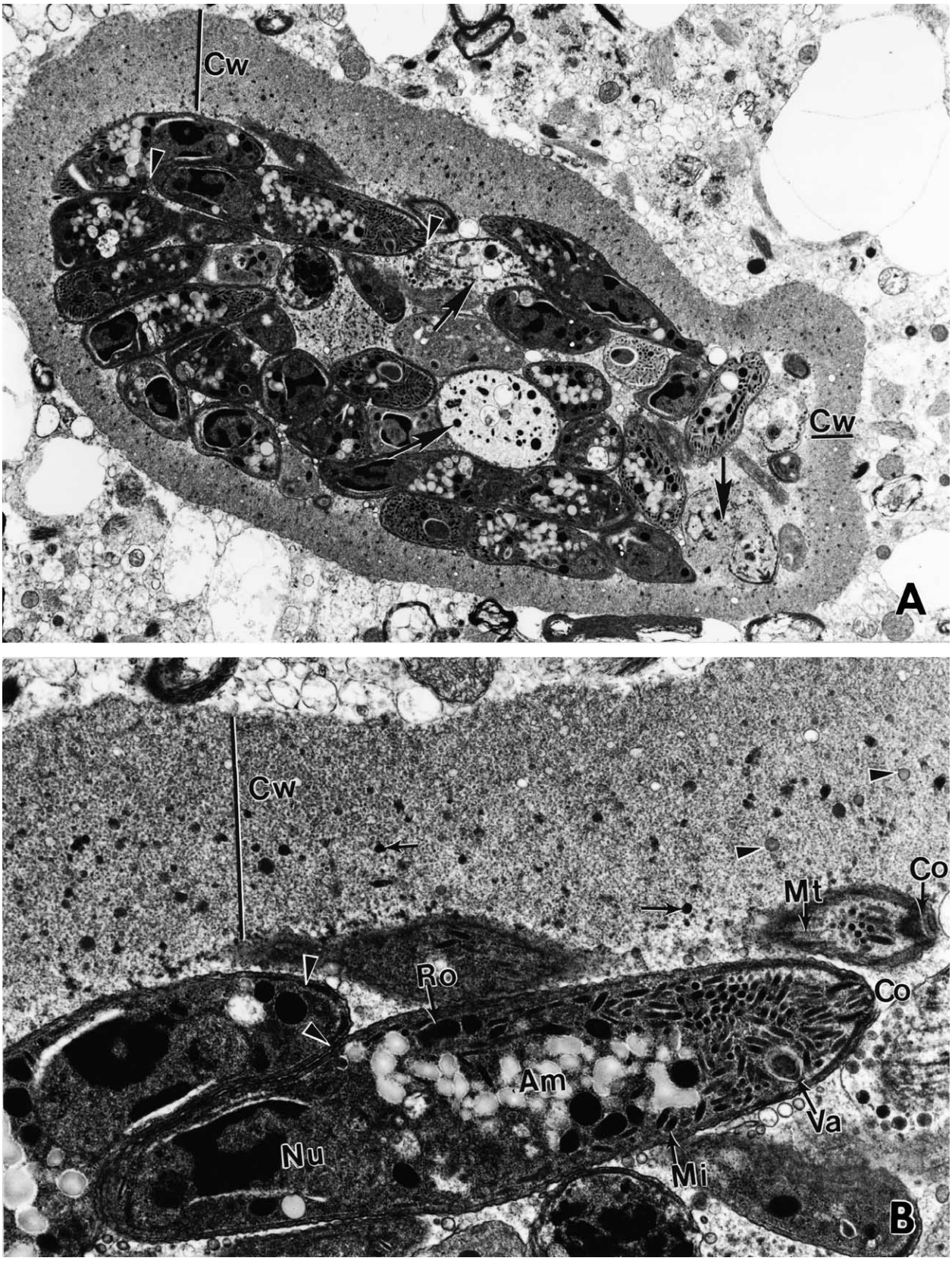

Fig. 2. TEM of a *Neospora caninum* tissue cyst in the cerebrum of dog no. 3. (A) Note varying thickness of the cyst wall (Cw), three degenerating bradyzoites (arrows), and a longitudinally cut bradyzoite (arrowheads). (B) Higher magnification of the longitudinally cut bradyzoite. The tissue cyst wall (Cw) is granular and contains electron-dense (arrows) and electron-lucent (arrowheads) bodies. Note conoid (Co), micronemes (Mi), amylopectin (Am), rhoptries (Ro), microtubules (Mt), nucleus (Nu), and membrane bound vacuoles (Va).

Fig. 3. TEM of a *Neospora caninum* tissue cyst in the cerebrum of dog no. 3. Note one bradyzoite with conoidal end (arrow) thicker than the nuclear end and the reverse arrangement in another bradyzoite (double arrowheads). Some bradyzoites are degenerating (Db). Also note membrane bound vacuole (Va) and an electron-dense collar at the conoidal end (two arrowheads), and rhoptries (Ro).

inflammation. One tissue cyst was seen in the meninges. The largest tissue cyst in histological section was 30 µm in diameter. Protozoa in the brain and in muscles stained positively with *N. caninum* polyclonal antibodies and BAG-1 antibodies, indicating they were bradyzoites.

3.2. Isolation in mice and gerbils

N. caninum was isolated by bioassays in mice from all three dogs. These isolates were designated NC-6, NC-7 and NC-8 from dog nos. 1, 2, 3, respectively.

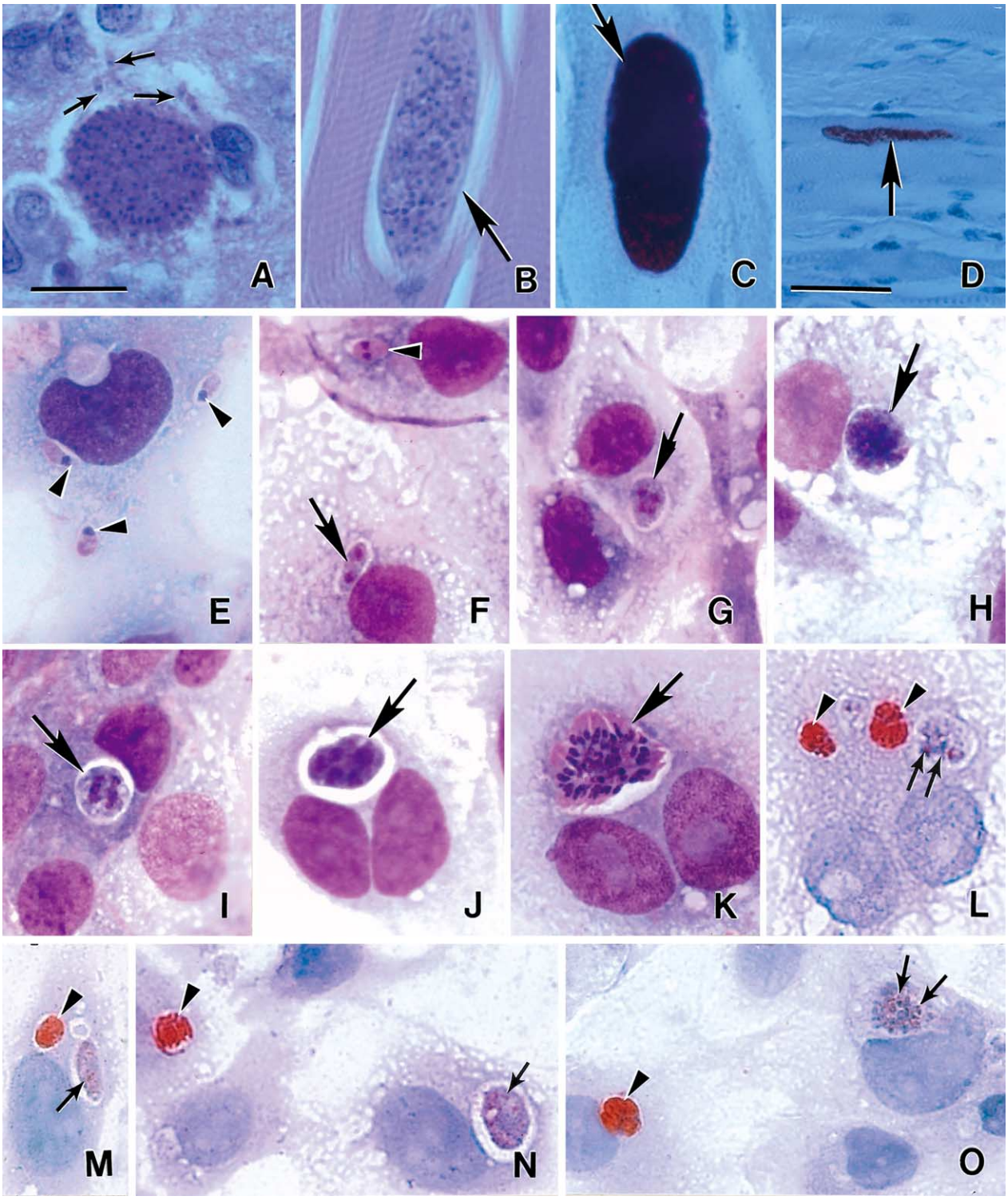

Fig. 4. Photomicrographs of *Neospora caninum,* A–D tissue cysts from canine tissues, E–O developmental stages of *N. caninum* in CV-1 cells seeded with bradyzoites released from Percoll-purified tissue cysts from dog no. 1. A and B = H and E, C and D = immunohistochemical staining with BAG-1 antibodies, E–K = Giemsa stain, L–O = immunohistochemical staining with polyclonal rabbit anti-*N. caninum* antibodies. Bar in A (20 μm) applies to all except D. Bar in D = 50 μm. (A) Rupturing tissue cyst in the cerebrum of dog no. 3. Note free bradyzoites (arrows) with terminal nuclei. (B and C) Tissue cysts with a thin cyst wall in the quadriceps of dog no. 2. (D) A group of BAG-1 positive parasites in oesophageal muscle of dog no. 1. (E) Three intracellular bradyzoites with terminal nuclei (arrowheads) 15 h. (F) Bi-nucleate schizont (arrow) and tachyzoites in endodyogeny (arrowhead) 40 h. (G) Four nucleated schizont (arrow) 64 h. (H) A schizont with undifferentiated nuclei (arrow) 64 h. (I) A schizont with eight nuclei (arrow) 64 h. (J) A schizont with at least 5 nuclei (arrow) 98 h. (K) A schizont (arrow) with many merozoites 98 h. (L–O) Note that the tachyzoites are stained bright red (arrowheads) and schizonts have small granules, especially the nucleoli, that stain red (small arrows). (L) One schizont and two groups of tachyzoites 64 h. (M) A schizont with one nucleus. The nucleolus is stained with antibody 64 h. (N) A schizont and a group of tachyzoites 98 h. (O) A schizont with several granules stained with *N. caninum* antibody 64 h.

The KO mice inoculated with brain tissue of all three dogs died from acute neosporosis; *N. caninum* tachyzoites were found in many organs. Non-suppurative myocarditis was the predominant lesion in these mice. All three isolates were infective to gerbils but pathogenicity was variable (Table 1). For example, all five gerbils inoculated s.c. with the NC-6 isolate died of acute neosporosis, whereas those inoculated with NC-7 and NC-8 remained asymptomatic (Table 1). The SW mice inoculated with all three isolates remained asymptomatic (Table 1).

3.3. Isolation of N. caninum in cell culture

N. caninum was isolated in cell cultures inoculated with material derived from all three dogs. In the culture seeded with brain homogenate of dog no. 1, no protozoa were detected during a 34-day observation period and the culture was discarded. However, *N. caninum* was grown in M 617 cells inoculated with lung tissue of a KO mouse that had been inoculated with brain tissue of dog no. 1. The culture of *N. caninum* from dog no. 1 (NC-6) was cryopreserved in liquid nitrogen on day 27 p.i.

Protozoal tachyzoites (NC-7) were first seen on day 5 or 6 after seeding cultures with digested or undigested brain material from dog no. 2. By day 36 p.i half of the monolayer was destroyed, and a portion of culture was cryopreserved in liquid nitrogen. *N. caninum* was also isolated in M 617 cells inoculated with lung homogenate of a KO mouse that had been inoculated with brain tissue from dog no. 2.

In cultures seeded with digested brain from dog no. 3, protozoa were first seen on day 6 p.i. and the culture was partially destroyed by growth of tachyzoites (NC-8) by day 70 p.i. when the culture was cryopreserved in liquid nitrogen.

3.4. In vitro development of N. caninum

In the culture initiated by purified tissue cysts from dog no. 1, intracellular bradyzoites could be seen by 15 h (Fig. 4E). By the 40th h, initiation of endodyogeny was noticed, as evident by the presence of zoites with indented or double nuclei (Fig. 4F). Two endodyogenous divisions were completed by 64 h and four zoites could be seen in the cells. By 90 h, groups with six zoites could be seen. Multiplication of the parasites resulted in large vacuoles containing numerous tachyzoites by 140 h. Rupture of infected cells was noticed by the eighth day and the monolayer was gradually destroyed by the third week.

Structures resembling schizogonous forms were noticed simultaneously with the endodyogonous forms (Fig. 4F–O). These zoites were much larger and contained a highly vesicular nucleus with a deeply basophilic cytoplasm. The nucleus was found to divide into 2, 3, 5 and above progressively, without any corresponding division of the cytoplasm (Fig. 4F–J). Thus, large spherical forms with numerous nuclei were seen by day 3 p.i. The schizonts were found to mature by day 3–4 p.i. and resulted in the release of numerous small zoites (Fig. 4K). However, the schizogonous forms disappeared by day 5 and could not be seen in the cover slip removed by 140 h. By immunohistochemical staining, the tachyzoites were stained brilliantly red whereas the schizonts were stained faintly and the staining was most evident in nucleoli (Fig. 4L–O). No staining was noticed in the coverslips infected with *T. gondii* tachyzoites.

3.5. Bioassay in dogs and cats

N. caninum oocysts were not found in the faeces of dogs and cats that were fed tissues from dog no. 2 and 3 during an observation period of 1 month. One of the four beagle dogs developed *N. caninum* antibodies at a titre of 1:80. Antibodies to *N. caninum* were not found in 1:20 dilution of sera of the remaining five dogs and the two cats, which remained asymptomatic. Protozoa were not identified in histological sections of dogs and cats.

3.6. Effect of storage on viability of N. caninum tissue cysts

The KO mice inoculated with tissue cysts stored at 4 °C for 7 and 10 days died of acute neosporosis 28 and 31 days later and tachyzoites were found in their lungs. Neither antibodies nor *N. caninum* was found in KO mice inoculated with tissue cysts stored for 23 and 31 days.

3.7. Molecular studies

The identity of the isolates was confirmed as *N. caninum* by PCR. Amplification of the 328 bp target fragment of the gene 5 region was observed with all the three isolates and positive control (NC-Original). No amplicons were noticed in the negative control. The gel-cleaned fragments were sequenced and the sequences of the canine isolates (accession nos. AY665720, AY665721, AY665722) and NC-Original (AY665719) were submitted to GenBank. All the sequences were identical.

The common *Toxoplasma* group primers yielded fragments of 399 bp from all isolates. The sequences of the canine isolates (GenBank accession nos. AY665716, AY665717, AY665718) were found to be identical among themselves as well as that of the NC-Original (AY665715).

None of the DNA samples produced any amplification with the *T. gondii*-specific SAG1 primers and *H. heydorni*-specific ITS-1 primers.

3.8. Serologic results

All three dogs had antibodies (NAT 1: 100 or more) to *N. caninum* at the time of necropsy. Antibodies to *T. gondii* were not found in 1:25 dilution of serum from any of

the three dogs or any of the rodents infected with the dog tissues. The results of NAT of rodents are given in Table 1.

4. Discussion

As stated earlier, the ultrastructure of only a few *N. caninum* tissue cysts has been examined because they are so few in number even in clinical specimens (Barr et al., 1991; Jardine, 1996; Bjerkås and Presthus, 1988; Bjerkås and Dubey, 1991; Speer et al., 1999). In the present study, the brain tissue was fixed directly in glutaraldehyde to preserve maximum morphologic detail. In general the structure of tissue cysts and bradyzoites was similar to those that have been described previously, including the presence of thick cyst walls, absence of tissue septa, rarity of micropores in bradyzoites, and the presence of a membrane-bound vesicular body (Barr et al., 1991; Bjerkås and Dubey, 1991; Jardine, 1996). However, there were additional findings. Jardine (1996) saw thick septa in a few tissue cysts from one dog, similar to those seen in tissue cysts (sarcocysts) of *Sarcocystis* species. In our opinion, these septa were either an artefact or some other parasite that was concurrently present in the dog reported by Jardine (1996). He also reported a layer of lipid-like bodies among bradyzoites (Jardine, 1996). We did not observe this structure in the tissue cysts in the present study, nor have we observed them in the past (Barr et al., 1991; Speer et al., 1999).

The number and arrangements of micronemes and rhoptries was highly variable. The micronemes in the present study were not arranged in any particular pattern. The bradyzoites studied by Jardine (1996); Bjerkås and Dubey (1991); Barr et al. (1991), and Peters et al. (2001), were often arranged perpendicular to the pellicle. There is also discrepancy concerning the number of rhoptries in *N. caninum* bradyzoites, which has been reported to be 6–12 (Bjerkås and Presthus, 1988; Barr et al., 1991; Speer et al., 1999). In the present study, the maximum number of rhoptries in any section was 3. Coccidian bradyzoites are often pointed at the conoidal end and broader at the non-conoidal nuclear end. In the present study, the conoidal end was broader than the nuclear end in many bradyzoites. To our knowledge there no published data on the measurement of *N. caninum* bradyzoites from smears. Most measurements were from longitudinal sections of selected bradyzoites in TEM preparations. Speer et al. (1999) gave the measurement of 16 bradyzoites as 8.1×2 μm ($6.5–10\times1.5–2.5$), a value that is much higher than found in the present study. According to Barr et al. (1990) bradyzoites from sections of tissue cysts in cattle were 5.9×1.4 μm ($5.5–7.0\times1.0–2.0$, $n=14$). Whether differences in measurements of bradyzoites reported by various authors are related to techniques is not known.

In the present study, tissue cyst-like structures were seen in skeletal muscles of all three dogs. The organisms in these groups were BAG-1 positive and they were surrounded by a thin (<0.5 μm) cyst wall. The number of these tissue cysts was too few to perform TEM. Peters et al. (2000, 2001) first reported tissue cysts in muscles of naturally-infected dogs and cattle from Germany. These tissue cysts were thin walled (0.3–1.0 μm thick), BAG-1-positive and contained bradyzoites that measured 5.2×1.6 μm ($n=10$).

The conoidal end of bradyzoites was stained more diffusely than the nuclear end and the diffuse conoidal end staining was probably due to staining of micronemes. The shape and size of the nucleus also varied. In some bradyzoites the nucleus was elongated (about 2 μm long) and occupied the distal one-fourth end of the bradyzoites, whereas in others the nucleus was approximately 1 μm long. There appeared to be a slight thickening of the pellicle of the polar ends of the bradyzoites and this thickening was more pronounced at the nuclear end. These pellicular thickenings were not reported previously in *N. caninum* bradyzoites.

Before the discovery of *N. caninum* oocyst in the faeces of dogs and coyotes (McAllister et al., 1998a; Lindsay et al., 1999; Gondim et al., 2004a) tachyzoites and bradyzoites were the only stages known. The oocyst is the product of sexual multiplication in the intestine of the definitive host. However, none of the asexual (schizonts) or sexual (gamonts) stages preceding the development of oocysts have been yet identified. In the present study, cell cultures were seeded with bradyzoites to study the conversion of bradyzoites into tachyzoites. The bradyzoites had converted to tachyzoites by 40 h p.i. Staining with *N. caninum* antibodies suggested that the unidentified stages were likely to be schizonts. However, these stages stained only faintly and this maybe due to the antigenic differences between tachyzoites and merozoites; the polyclonal antibodies used herein were raised against tachyzoites (Lindsay and Dubey, 1989a). Dogs that have excreted *N. caninum* oocysts often do not have serum antibodies that recognise tachyzoites (McAllister et al., 1998a; Lindsay et al., 1999). DNA of neither *H. heydorni* nor *T. gondii* was demonstrable in the parasites seeded on to cell cultures. Further the staining appeared to be specific because the schizont nucleoli consistently stained with the antibodies and these structures were absent in control cover slips infected with *T. gondii*. So contamination with these organisms seems unlikely. Additionally, tissue cysts in the inoculum had the morphology of *N. caninum*. The results could not be repeated because tissue cysts were not available. Further studies are needed to confirm the identity of these schizont-like stages.

Little is known of the biology of *N. caninum* tissue cysts and bradyzoites. Although tissue cysts have been produced in experimentally-infected mice (Lindsay and Dubey, 1989b; McGuire et al., 1997), cats (Dubey et al., 1990), sheep (McAllister et al., 1996a), and gerbils (Basso et al., 2001), their numbers are low and recoveries were not consistent and so it is difficult to study the biology of bradyzoites. The production of *N. caninum* oocysts is

another enigma. Only a few *N. caninum* oocysts have been found in naturally-infected dogs (Basso et al., 2001; McGarry et al., 2003) and even in experimentally-infected dogs and coyotes their numbers are low (Gondim et al., 2002, 2004a). Therefore, searching for the entero-epithelial stages of *N. caninum* preceding the development of oocysts in the intestines of dogs has not been successful.

The lack infectivity of *N. caninum* tissue cysts to cats and dogs in the present study is unexplained. The cats and dogs consumed more than 2 kg of dog tissues heavily infected with *N. caninum*; based on smears and sections, thousands of tissue cysts were present in tissues. Further tissue cysts were infective to mice. McAllister et al. (1998b) had reported that tissue cysts of three *N. caninum* strains were not infective to cats.

In the present study tissue cysts survived in unhomogenised brain tissue for 7 and 10 days at 4 °C without any preservative and these were infective to KO mice by the oral route, confirming earlier findings. Lindsay et al. (1992) reported that tissue cysts in brains of experimentally infected mice survived for 7 days but not 14 days at 4 °C. The duration of survival of *N. caninum* in tissues of dead animals is an unknown but is important factor in the natural epidemiology of this disease. White-tailed deer and cattle whose carcasses may be preyed on by dogs and coyotes appear to be the natural intermediate hosts for *N. caninum* and it seems likely that *N. caninum* will survive in them long enough for transmission to occur.

Sequence analysis at two different genetic loci provided additional confirmation of the identity of the three isolates as *N. caninum*. Further, the lack of amplification with *T. gondii* and *H. heydorni*-specific primer sets ruled out the presence of both *T. gondii* and *H. heydorni* in the dogs.

The sequences of both the gene 5 and ITS-1 fragments from the three isolates were identical to each other. However, this similarity cannot be used as a means to substantiate the theory of vertical transmission of *N. caninum* from the dam to the dogs, as the sequences were also identical to that of the NC-Original and to those in the public database. Information about genetic diversity among different geographical isolates of *N. caninum* is scanty (Schock et al., 2001; Gondim et al., 2004b). New genetic markers and animal models are needed to study genetic and biologic diversity of *N. caninum* isolates. Isolates of *N. caninum* from littermate dogs provides a unique opportunity to study these aspects of the biology of *N. caninum.*

In the present study, both thin and thick walled tissue cysts were found in littermate dogs and these were identified as *N. caninum* based upon morphology, PCR, isolation in cell culture and in animals, and serology. All three dogs had antibodies to *N. caninum* and no antibodies to *T. gondii,* and importantly, cats fed tissues from two dogs heavily infected with tissue cysts did not shed *T. gondii* oocysts. This distinction is important because dogs can harbour *T. gondii* and *N. caninum* concurrently (Dubey et al., 1995). Cats were fed canine tissues because they become infected with *T. gondii* and shed oocysts after ingesting even few bradyzoites (Dubey, 2001).

Acknowledgements

The authors thank John Jenkins, Department of Veterinary Pathology Armed Forces Institute, Washington, DC for electron micrographs, and Katherine Hopkins and S.K. Shen, USDA, for technical assistance.

Note added in proof

The identity of *N. caninum* schizonts was confirmed in cell cultures 24–130 h p.i. with bradyzoites from Percoil separated tissue cysts from the brains of gerbils inoculated with NC-6 and NC-7 isolates from dog nos. 1 and 2.

References

Barr, B.C., Conrad, P.A., Dubey, J.P., Anderson, M.L., 1991. *Neospora*-like encephalomyelitis in a calf: pathology, ultrastructure, and immunoreactivity. J. Vet. Diagn. Invest. 3, 39–46.

Basso, W., Venturini, L., Venturini, M.C., Hill, D.E., Kwok, O.C.H., Shen, S.K., Dubey, J.P., 2001. First isolation of *Neospora caninum* from the feces of a naturally infected dog. J. Parasitol. 87, 612–618.

Bjerkås, I., Dubey, J.P., 1991. Evidence that *Neospora caninum* is identical to the *Toxoplasma*-like parasite of Norwegian dogs. Acta Vet. Scand. 32, 407–410.

Bjerkås, I., Presthus, J., 1988. Immuno-histochemical and ultrastructural characteristics of a cyst-forming sporozoon associated with encephalomyelitis and myositis in dogs. Acta Pathol. Microbiol. Immunol. Scand. 96, 445–454.

Dubey, J.P., 1995. Duration of immunity to shedding of *Toxoplasma gondii* oocysts by cats. J. Parasitol. 81, 410–415.

Dubey, J.P., Metzger, F.L.Jr., Hattel, A.L., Lindsay, D.S., Fritz, D.L., 1995. Canine cutaneous neosporosis: clinical improvement with clindamycin. Vet. Dermatol. 6, 37–43.

Dubey, J.P., 1998. Refinement of pepsin digestion method for isolation of *Toxoplasma gondii* from infected tissues. Vet. Parasitol. 74, 75–77.

Dubey, J.P., 2001. Oocyst shedding by cats fed isolated bradyzoites and comparison of infectivity of bradyzoites of the VEG strain *Toxoplasma gondii* to cats and mice. J. Parasitol. 87, 215–219.

Dubey, J.P., 2003. Review of *Neospora caninum* and neosporosis in animals. Korean J. Parasitol. 41, 1–16.

Dubey, J.P., Desmonts, G., 1987. Serological responses of equids fed *Toxoplasma gondii* oocysts. Equine Vet. J. 19, 337–339.

Dubey, J.P., Lindsay, D.S., 1996. A review of *Neospora caninum* and neosporosis. Vet. Parasitol. 67, 1–59.

Dubey, J.P., Sreekumar, C., 2003. Redescription of *Hammondia hammondi* and its differentiation from *Toxoplasma gondii*. Int. J. Parasitol. 33, 1437–1453.

Dubey, J.P., Hattel, A.L., Lindsay, D.S., Topper, M.J., 1988. Neonatal *Neospora caninum* infection in dogs: isolation of the causative agent and experimental transmission. J. Am. Vet. Med. Assoc. 193, 1259–1263.

Dubey, J.P., Lindsay, D.S., Lipscomb, T.P., 1990. Neosporosis in cats. Vet. Pathol. 27, 335–339.

Dubey, J.P., Dorough, K.R., Jenkins, M.C., Liddell, S., Speer, C.A., Kwok, O.C.H., Shen, S.K., 1998. Canine neosporosis: clinical signs, diagnosis, treatment and isolation of *Neospora caninum* in mice and cell culture. Int. J. Parasitol. 28, 1293–1304.

Dubey, J.P., Garner, M.M., Stetter, M.D., Marsh, A.E., Barr, B.C., 2001. Acute *Sarcocystis falcatula*-like infection in a carmine bee-eater (*Merops nubicus*) and immunohistochemical cross reactivity between *Sarcocystis falcatula* and *Sarcocystis neurona*. J. Parasitol. 87, 824–831.

Dubey, J.P., Barr, B.C., Barta, J.R., Bjerkås, I., Björkman, C., Blagburn, B.L., Bowman, D.D., Buxton, D., Ellis, J.T., Gottstein, B., Hemphill, A., Hill, D.E., Howe, D.K., Jenkins, M.C., Kobayashi, Y., Koudela, B., Marsh, A.E., Mattsson, J.G., McAllister, M.M., Modrý, D., Omata, Y., Sibley, L.D., Speer, C.A., Trees, A.J., Uggla, A., Upton, S.J., Williams, D.J.L., Lindsay, D.S., 2002. Redescription of *Neospora caninum* and its differentiation from related coccidia. Int. J. Parasitol. 32, 929–946.

Gondim, L.F.P., Gao, L., McAllister, M.M., 2002. Improved production of *Neospora caninum* oocysts, cyclical transmission between dogs and cattle, and in vitro isolation from oocysts. J. Parasitol. 88, 1159–1163.

Gondim, L.F.P., McAllister, M.M., Pitt, W.C., Zemlicka, D.E., 2004a. Coyotes (*Canis latrans*) are definitive hosts of *Neospora caninum*. Int. J. Parasitol. 34, 159–161.

Gondim, L.F.P., Laski, P., Gao, L., McAllister, M.M., 2004b. Variation of the internal transcribed spacer 1 sequence within individual strains and among different strains of *Neospora caninum*. J. Parasitol. 90, 119–122.

Jardine, J.E., 1996. The ultrastructure of bradyzoites and tissue cysts of *Neospora caninum* in dogs: absence of distinguishing morphological features between parasites of canine and bovine origin. Vet. Parasitol. 62, 231–240.

Lindsay, D.S., Dubey, J.P., 1989a. Immunohistochemical diagnosis of *Neospora caninum* in tissue sections. Am. J. Vet. Res. 50, 1981–1983.

Lindsay, D.S., Dubey, J.P., 1989b. *Neospora caninum* (Protozoa: Apicomplexa) infections in mice. J. Parasitol. 75, 772–779.

Lindsay, D.S., Blagburn, B.L., Dubey, J.P., 1992. Factors affecting the survival of *Neospora caninum* bradyzoites in murine tissues. J. Parasitol. 78, 70–72.

Lindsay, D.S., Dubey, J.P., Duncun, R.B., 1999. Confirmation that the dog is a definitive host for *Neospora caninum*. Vet. Parasitol. 82, 327–333.

McAllister, M.M., McGuire, A.M., Jolley, W.R., Lindsay, D.S., Trees, A.J., Stobart, R.H., 1996a. Experimental neosporosis in pregnant ewes and their offspring. Vet. Parasitol. 33, 647–655.

McAllister, M.M., Parmley, S.F., Weiss, L.M., Welch, V.J., McGuire, A.M., 1996b. An immunohistochemical method for detecting bradyzoite antigen (BAG5) in *Toxoplasma gondii*-infected tissues cross-reacts with a *Neospora caninum* bradyzoite antigen. J. Parasitol. 82, 354–355.

McAllister, M.M., Dubey, J.P., Lindsay, D.S., Jolley, W.R., Wills, R.A., McGuire, A.M., 1998a. Dogs are definitive hosts of *Neospora caninum*. Int. J. Parasitol. 28, 1473–1478.

McAllister, M.M., Jolley, W.R., Wills, R.A., Lindsay, D.S., McGuire, A.M., Tran's, J.D., 1998b. Oral inoculation of cats with tissue cysts of *Neospora caninum*. Am. J. Vet. Res. 59, 441–444.

McGarry, J.W., Stockton, C.M., Williams, D.J.L., Trees, A.J., 2003. Protracted shedding of oocysts of *Neospora caninum* by a naturally infected foxhound. J. Parasitol. 89, 628–630.

McGuire, A.M., McAllister, M.M., Jolley, W.R., 1997. Separation and cryopreservation of *Neospora caninum* tissue cysts from murine brain. J. Parasitol. 83, 319–321.

Peters, M., Wagner, F., Schares, G., 2000. Canine neosporosis: clinical and pathological findings and first isolation of *Neospora caninum* in Germany. Parasitol. Res. 86, 1–7.

Peters, M., Lütkefels, E., Heckeroth, A.R., Schares, G., 2001. Immunohistochemical and ultrastructural evidence for *Neospora caninum* tissue cysts in skeletal muscles of naturally infected dogs and cattle. Int. J. Parasitol. 31, 1144–1148.

Romand, S., Thulliez, P., Dubey, J.P., 1998. Direct agglutination test for serologic diagnosis of *Neospora caninum* infection. Parasitol. Res. 84, 50–53.

Sibley, L.D., Boothroyd, J.C., 1992. Virulent strains of *Toxoplasma gondii* comprise a single clonal lineage. Nature 39, 82–85.

Schock, A., Innes, E.A., Yamane, I., Latham, S.M., Wastling, J.M., 2001. Genetic and biological diversity among isolates of *Neospora caninum*. Parasitology 123, 13–23.

Šlapeta, J.R., Koudela, B., Votypka, J., Modry, D., Horejs, R., Lukes, J., 2002. Coprodiagnosis of *Hammondia heydorni* in dogs by PCR based amplification of ITS 1 rRNA: differentiation from morphologically indistinguishable oocysts of *Neospora caninum*. Vet. J. 163, 147–154.

Speer, C.A., Dubey, J.P., McAllister, M.M., Blixt, J.A., 1999. Comparative ultrastructure of tachyzoites, bradyzoites, and tissue cysts of *Neospora caninum* and *Toxoplasma gondii*. Int. J. Parasitol. 29, 1509–1519.

Sreekumar, C., Hill, D.E., Fournet, V.M., Rosenthal, B.M., Lindsay, D.S., Dubey, J.P., 2003. Detection of *Hammondia heydorni*-like organisms and their differentiation from *Neospora caninum* using random-amplified polymorphic DNA-polymerase chain reaction. J. Parasitol. 89, 1082–1085.

Yamage, M., Flechtner, O., Gottstein, B., 1996. *Neospora caninum*: specific oligonucleotide primers for the detection of brain 'cyst' DNA of experimentally-infected nude mice by the polymerase chain reaction (PCR). J. Parasitol. 82, 272–279.