Parasitol Res (2005) 95: 413–419
DOI 10.1007/s00436-004-1286-2

ORIGINAL PAPER

Hany M. Elsheikha · Benjamin M. Rosenthal
Linda S. Mansfield

Dexamethasone treatment induces susceptibility of outbred Webster mice to experimental infection with *Besnoitia darlingi* isolated from opossums (*Didelphis virginiana*)

Received: 8 June 2004 / Accepted: 23 November 2004 / Published online: 10 March 2005
© Springer-Verlag 2005

Abstract The Sarcocystidae comprise a diverse, monophyletic apicomplexan parasite family, most of whose members form intracellular cysts in their intermediate hosts. The extent of pathology associated with such cyst formation can range widely. We currently lack experimental animal models for many of these infections. Here we explored dexamethasone treatment as a means to render outbred mice susceptible to *Besnoitia darlingi* infection and demonstrated that this approach allows viable parasites to be subsequently isolated from these mice and maintained in tissue culture. *Besnoitia* bradyzoites recovered from crushed cysts derived from naturally infected opossums (*Didelphis virginiana*) replicated and reproduced the development of besnoitiosis in mice treated with dexamethasone (0.5 mg/ml drinking water) daily for 12 days post infection (DPI). Isolates recovered from the peritoneal exudates of these mice were viable and were maintained in long-term tissue cultures. In contrast, control mice given saline without dexamethasone and challenged with similar bradyzoites remained clinically normal for up to 70 DPI. An additional group of mice challenged with the same inoculum of bradyzoites and given dexamethasone at the same concentration and treated with sulfadiazine (1 mg/ml drinking water) daily for 12 DPI also remained normal for up to 70 DPI. Severe disease developed more rapidly in dexamethasone-treated mice inoculated with culture-derived *B. darlingi* tachyzoites than in those inoculated with cyst-derived bradyzoites. *B. darlingi* tachyzoite-infected, untreated control mice developed signs of illness at 18 DPI. In contrast, mice treated with sulfadiazine showed no clinical signs up to 50 DPI. Although dexamethasone treatment was required to establish *B. darlingi* infection in outbred mice inoculated with opossum-derived *B. darlingi* bradyzoites, no such treatment was required for mice inoculated with culture-derived *B. darlingi* tachyzoites. Finally, sulfadiazine was highly effective in protecting mice from infection with the tachyzoite stage of *B. darlingi*.

H. M. Elsheikha · L. S. Mansfield
Department of Large Animal Clinical Sciences,
College of Veterinary Medicine, Michigan State University,
East Lansing, MI 48824, USA

B. M. Rosenthal
Animal Diseases Parasite Laboratory,
Agricultural Research Service,
United States Department of Agriculture,
Agricultural Research Center, Animal and Natural
Resources Institute, Building 1080, BARC-East,
Beltsville, MD 20705-2350, USA

L. S. Mansfield
Department of Microbiology and Molecular Genetics,
College of Veterinary Medicine, Michigan State University,
East Lansing, MI 48824, USA

L. S. Mansfield (✉)
Michigan State University,
B43 Food Safety and Toxicology Bldg.,
East Lansing, MI 48824, USA
E-mail: mansfie4@cvm.msu.edu
Tel.: +1-517-4323100
Fax: +1-517-4322310

Introduction

Apicomplexan parasites belonging to the coccidian genus *Besnoitia* are prevalent in some domestic and wild animals and can cause the clinical disease termed besnoitiosis. *Besnoitia darlingi* is a heteroxenous coccidian employing opossums (*Didelphis virginiana*) as the intermediate host and cats as the definitive host (Dubey et al. 2002). Opossums become infected with *B. darlingi* by ingesting infected tissues containing cysts via carnivorism, by ingesting food or water contaminated with oocysts excreted by infected cats, or by experimental inoculation of tachyzoites (Smith and Frenkel 1977). In the United States, *B. darlingi* has been reported from opossums from many regions (Elsheikha et al. 2003).

Few experimental models are available for studying the diverse assemblage of tissue cyst-forming coccidia including *Besnoitia* spp. A cheap, effective animal model and the ability to passage the parasite in cell culture would aid the study of this poorly characterized parasite species. Different animal models have been used to isolate *Besnoitia* species, including outbred laboratory mice (*Mus musculus*), interferon-gamma gene knockout (γ-IFN-KO) mice, rats, gerbils, guinea pigs, hamsters, and rabbits (Senaud et al. 1974; Schneider 1976; Shkap et al. 1987; Dubey et al. 2002). Corticosteroids have proven useful in developing animal models to study coccidian parasitism (Dubey et al. 1974; Boy et al. 1990; Fenger et al. 1997; Cutler et al. 2001) because they suppress natural killer (NK) cell activity by acting directly on NK effector cells and they inhibit differentiation and antigen presentation by dendritic cells (Cox et al. 1982; Pan et al. 2001). Therefore, we tested the hypothesis that corticosteroids facilitate the development of *Besnoitia* in outbred laboratory mice thus providing an inexpensive experimental model.

Materials and methods

Naturally infected opossums

Two adult female Virginia opossums (*D. virginiana*) were captured on farms in Ingham County, located in central Michigan (42°38′29″to 42°31′21″N) and (84°20′36″ to 84°34′28″W), USA during the summer of 2002.

Gross pathology

Autopsies were performed immediately after humane euthanasia of the opossums using slowly increasing concentrations of CO_2 according to our AUCAUC approval and AVMA guidelines. All visceral organs, skeletal muscles, and external body surfaces were visually screened for the presence of white cysts suggestive of *Besnoitia* spp. One cyst from each opossum was crushed between a glass microscope slide and coverslip. After crushing, a white viscous fluid was released. Unstained and Giemsa-stained smears of this material were examined microscopically.

Microscopic examination

Tissues containing cysts found in necropsied opossums were fixed in 10% neutral buffered formalin, embedded in paraffin, sectioned at 5 μm, stained with hematoxylin and eosin (H&E), and examined using light microscopy. Measurements of cysts were taken from histological sections using a light microscope equipped with a calibrated ocular micrometer at 400× and 1,000× magnifications. Minimum and maximum values for cyst length and width are given followed in parentheses by mean, standard deviation, and number of sections examined. A sample from hepatic tissue containing a cyst was processed for transmission electron microscopy (TEM) as described (Elsheikha et al. 2003, 2004).

Preparation of parasite materials

Besnoitia cysts isolated from opossums during necropsy were kept for ~3–4 weeks at 4°C in sterile normal saline with 10,000 U ml^{-1} of penicillin G sodium, 10,000 μg ml^{-1} of streptomycin, and 1.25 μg ml^{-1} of fungizone before being used in mouse inoculations. Cysts isolated from each opossum were gently opened on a sterile microscope glass slide using scalpels and forceps under sterile conditions. Whitish material obtained from the disrupted cysts was diluted and washed twice with sterile 0.85% NaCl solution plus the same concentrations of the antibiotic-antimycotic mixture by centrifugation in a CR/CT4.12 centrifuge with a M4 swinging bucket rotor (Forma Scientific, Marietta, Ohio) at 1,500 g for 5 min at 4°C. The final pellet of bradyzoites was resuspended in a few ml of saline solution with antibiotic-antimycotic mixture as described above. The number of bradyzoites were counted using a hemocytometer chamber at 200× magnification on a light microscope (Reichert-Jung, Pegasus Scientific, Frederick, Md.) and the concentration adjusted.

Animals used for experimental infection

Outbred Swiss Webster female albino mice 6–7 weeks old were purchased from Taconic farms (Germantown, N.Y.). The mice were quarantined and examined every day for signs of illness. They were monitored by periodic tape tests for ectoparasites and fecal flotation for endoparasites. Results of all screening tests were negative. Mice were maintained and received humane care at the MSU Laboratory Animal Resources facility using standard procedures. All described procedures were approved by the Institutional Animal Care and Use Committee and conducted in compliance with accepted standards of the Guideline for the Care and Use of Laboratory Animals (NIH Publication 86-23, revised 1996). Thereafter, mice were acclimatized for at least 1 week prior to injection with approximately 0.5 ml of the bradyzoite or tachyzoite suspension (Table 1).

Infectivity of opossum-derived materials in mice

Three mice were assigned to each of six groups. Four of these groups were treated with dexamethasone (Catalogue no. D4902; 0.5 mg/ml drinking water) while the other two were treated with sulfadiazine lot no. 81K1620 (1 mg/ml of drinking water) to establish whether sulfadiazine protects mice against infection or cyst formation.

Table 1 Transmission of *Besnoitia darlingi* from opossums to Swiss Webster outbred mice

Group no.	No. of mice	Inoculum (dose)	Route	Day of necropsy[d]	Treatment[f]	Parasite[g]
1	3[a]	Bradyzoites (4×10^5)	IP	KD 13–15	Dexamethasone	Liv, Sp, Pex[h]
2	3[a]	Bradyzoites (4×10^5)	SC	KD 15–16	Dexamethasone	Liv, Sp, Pex
3	3[b]	Bradyzoites (4×10^5)	IP	KD 15–17[e]	Dexamethasone	Liv, Sp, Pex[h]
4	3[b]	Bradyzoites (4×10^5)	SC	KD 15–16	Dexamethasone	Liv, Sp, Pex
5	3[a]	Bradyzoites (4×10^5)	SC	K 70	Sulfadiazine	Negative
6	3[b]	Bradyzoites (4×10^5)	IP	K 60	Sulfadiazine	Negative
7	2a	Bradyzoites (4×10^5)	IP	K 70	Untreated	Liv
8	3[c]	Tachyzoites (4×10^5)	IP	D 9–10	Dexamethasone	Liv, Sp, Pex, L
9	3[c]	Tachyzoites (4×10^5)	IP	KD 50	Sulfadiazine	Negative
10	4[c]	Tachyzoites (4×10^5)	IP	D 18	Untreated	Liv, Sp, Pex, L

[a]Mice inoculated by bradyzoites derived from ear cysts of first opossum
[b]Mice inoculated by bradyzoites derived from liver and lung cysts of second opossum
[c]Mice in group 8, 9, and 10 were inoculated by culture-derived tachyzoites obtained from mice in groups 1 and 3
[d]*KD* killed when diseased, *D* found dead, *IP* intraperitoneal, *SC* subcutaneous
[e]One mouse in this group was found dead at 16 DPI
[f]All drug treatments were given in drinking water starting from day 3 to 15 post inoculation
[g]*Liv* liver, *Sp* spleen, *Pex* peritoneal exudate, *L* lung
[h]Tachyzoites used for cell culture and for cryopreservation

All drug treatments (dexamethasone and sulfadiazine) commenced on the 3rd day post inoculation (DPI) and were maintained for 12 days. Dexamethasone and sulfadiazine were purchased from Sigma-Aldrich (St. Louis, Mo., USA). To investigate whether the route of inoculation or the source of the isolates affected the outcome of infection, mice were inoculated with (~0.5 ml suspension) of two different *B. darlingi* isolates via two different routes (Table 1). An additional group of two infected, untreated mice was used as positive controls. All mice were examined once daily for the development of clinical signs. At necropsy, 13–17 DPI, a complete gross post-mortem examination of all visceral organs was conducted. Additionally, several 5 μm histological sections of liver, spleen, lung, heart, brain, and kidneys were made. Stained sections were examined using a Reichert-Jung microscope (Pegasus Scientific, Frederick, Md.). The volume of peritoneal exudates was assessed for any changes in quantity. The volume of the peritoneal exudate was evaluted and scored semi-quantitaively as slight (<0.5 ml), medium (0.5–1.0 ml), and large ($\geq$1.0 ml). Fisher's exact test ($P<0.5$) was used to detect the link between the route of parasite inoculation and quantity of peritoneal exudate produced.

Maintenance in tissue culture cells

At necropsy, parasites in the peritoneal fluid from all mice treated with dexamethasone was collected using a syringe and washed twice in 0.85% sterile normal saline and 0.25 ml of each exudate was inoculated directly onto 25-cm^2 tissue culture flasks with a 60–80% confluent monolayer of bovine turbinate (BT) cells (ATCC, CRL-1390, American Type Culture Collection, Manassas, Va.). BT cells were maintained as described (Elsheikha et al. 2004). Cultures were monitored daily using an inverted microscope (Carl Zeiss, Opton, Columbia, Md.) to follow the development of plaques. To document the development of the parasites at 24 h intervals for 2 weeks, parasites harvested from the culture flask were directly inoculated onto 12-mm^2 glass coverslips containing a confluent monolayer of BT cells and incubated in a 24-well tissue culture plate at 37°C and 5% CO_2. Each day for 2 weeks, coverslips of infected BT cells were removed from culture and fixed in 10% formalin for 30 min, placed in 100% methanol for 10 min at room temperature, stained with Giemsa, attached to glass microscopic slides with Permount (Fisher Scientific, Fair Lawn, N.J.) and examined by light microscopy (Reichert-Jung) to follow the progress of parasite development.

Infectivity of culture-derived materials in mice

B. darlingi tachyzoites harvested from tissue culture flasks were washed twice in sterile 1× PBS and separated from host cells and large schizonts by filtration through PD-10 columns filled with Sephadex (Amersham-Biosciences, Piscataway, N.J., USA). Free tachyzoites were counted using a hemocytometer, and diluted to defined concentrations using procedures similar to those described above for bradyzoites. These culture-derived tachyzoites were used to inoculate ten mice (Table 1). These mice were divided into three groups: one group treated with dexamethasone, a second treated with sulfadiazine, and a control group that remained untreated. Dexamethasone and sulfadizine were administered as previously described (Table 1).

Molecular phylogenetics

DNA was extracted from tachyzoites derived from peritoneal exudates of experimentally inoculated mice

with the *B. darlingi* isolate MIBD1 using DNeasy tissue kit (Qiagen, Valencia, Calif.). The first internal transcribed spacer (ITS-1) region was amplified using primers 69 and 70 (Tanhauser et al. 1999). Direct DNA sequencing of the PCR-amplified parasite ITS-1 gene from this isolate was compared to previously studied *B. darlingi* and other *Besnoitia* spp. (Dubey et al. 2002). Sequence chromatograms generated using BigDye v.2 chemistries and an ABI 3100 fluorescent sequencer were aligned and edited using Sequencher (Genecodes, Ann Arbor, Mich.) and compared to all coccidian homologues available for comparison. Pairwise distances were calculated using Kimura's 2-parameter (K2P) method and used as the basis for phylogenetic reconstruction of midpoint rooted trees using the neighbor joining (NJ) method, as implemented in MEGA v.2.1 (Kumar et al. 2001). The sensitivity of the resulting topology to sampling variance was evaluated by repeating the analysis on 1,000 bootstrap replicates of the original alignment. Optimal trees were also sought under a heuristic search using the criterion of maximum parsimony with unweighted characters, as implemented by MEGA.

Results

Pathology of besnoitiosis in naturally infected opossums

Gross examination revealed the physical condition of these captive opossums to be poor. In one opossum, numerous macroscopic cysts were observed in all visceral organs, tongue, abdominal muscles, and diaphragm. The second opossum had similar cysts only in the ears. In Giemsa-stained smears prepared from organisms contained within the cysts, the cystozoites appeared crescent-shaped. Histological findings were similar to those previous reported (Dubey et al. 2002). The cysts recovered from opossums were characteristic of *B. darlingi* (Fig. 1). TEM showed that tissue cysts and bradyzoites were similar to those of other species of *Besnoitia* (Paperna and Lainson 2001; Dubey et al. 2002).

Establishment of an outbred laboratory mouse model of *B. darlingi*

Dexamethasone-treated mice inoculated with *B. darlingi* tachyzoites rapidly developed severe signs of illness and all mice were found dead at 9–10 DPI. Dexamethasone-untreated, infected mice also developed severe clinical signs but at a later time (18 DPI). Clinical signs included depression, a ruffled hair coat, head-pressing, anorexia, dehydration, weight loss, and a hunched appearance. Gross and histopathological hepatic lesions were compatible with the outwardly visible signs of disease. Necropsy of these mice revealed severe hepatosplenomegaly. Acute diffuse fatty changes in the liver was observed associated with clusters of lymphocytes and megakaryocytes as well as free tachyzoites and schizonts (Fig. 2A, B). In contrast, mice supplemented with sulfadiazine on a daily basis were completely protected and lived for up to 50 DPI without demonstrating any clinical signs or pathological lesions. Bradyzoite-infected mice demonstrated clinical manifestations, and gross, and microscopical lesions similar to those observed in the tachyzoite-treated mice.

Additionally, bradyzoite-infected, dexamethasone-treated mice had pronounced clinical signs by the end of the second week of infection. Bradyzoite-infected mice not given dexamethasone showed no clinical signs and no gross lesions when necropsied at 70 DPI. However, microscopic examination revealed the presence of degenerating cysts in the liver surrounded by mild lymphohistiocytic infiltration with some neutrophils (Fig. 2C). Multifocal random caseation necrosis occurred with neutrophil infiltration (Fig. 2D). Kupffer cells lining the hepatic sinusoides were hypertrophied. Pigment-laden Kupffer cells also were present in the portal area. A diffuse hepatic lipidosis was noted and

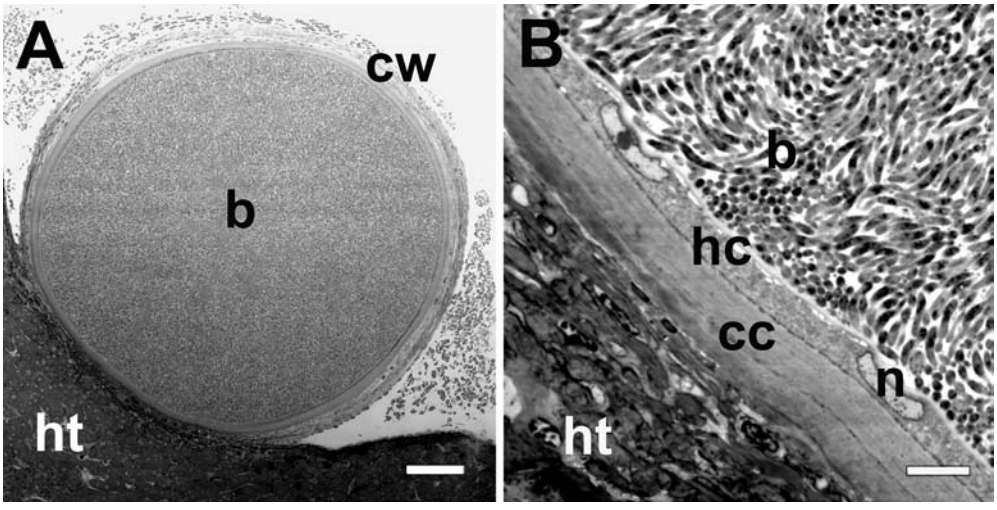

Fig. 1 A Photomicrograph of a *Besnoitia darlingi* cyst isolated from lung tissue of a naturally infected opossum (*Didelphis virginiana*) showing the cyst wall capsule (*cw*) enclosing myriads of bradyzoites (*b*), and host tissue (*ht*). **B** A higher magnification of part of the cyst illustrating the host tissue (*ht*) surrounding the thick cyst capsule (*cc*), host cell cytoplasm (*hc*) with elongated nuclei (*n*), and a vacuole containing numerous bradyzoites (*b*). Toluidine blue and basic fuchsin stain. *Scale bars* in μm; **A** = 50, **B** = 10

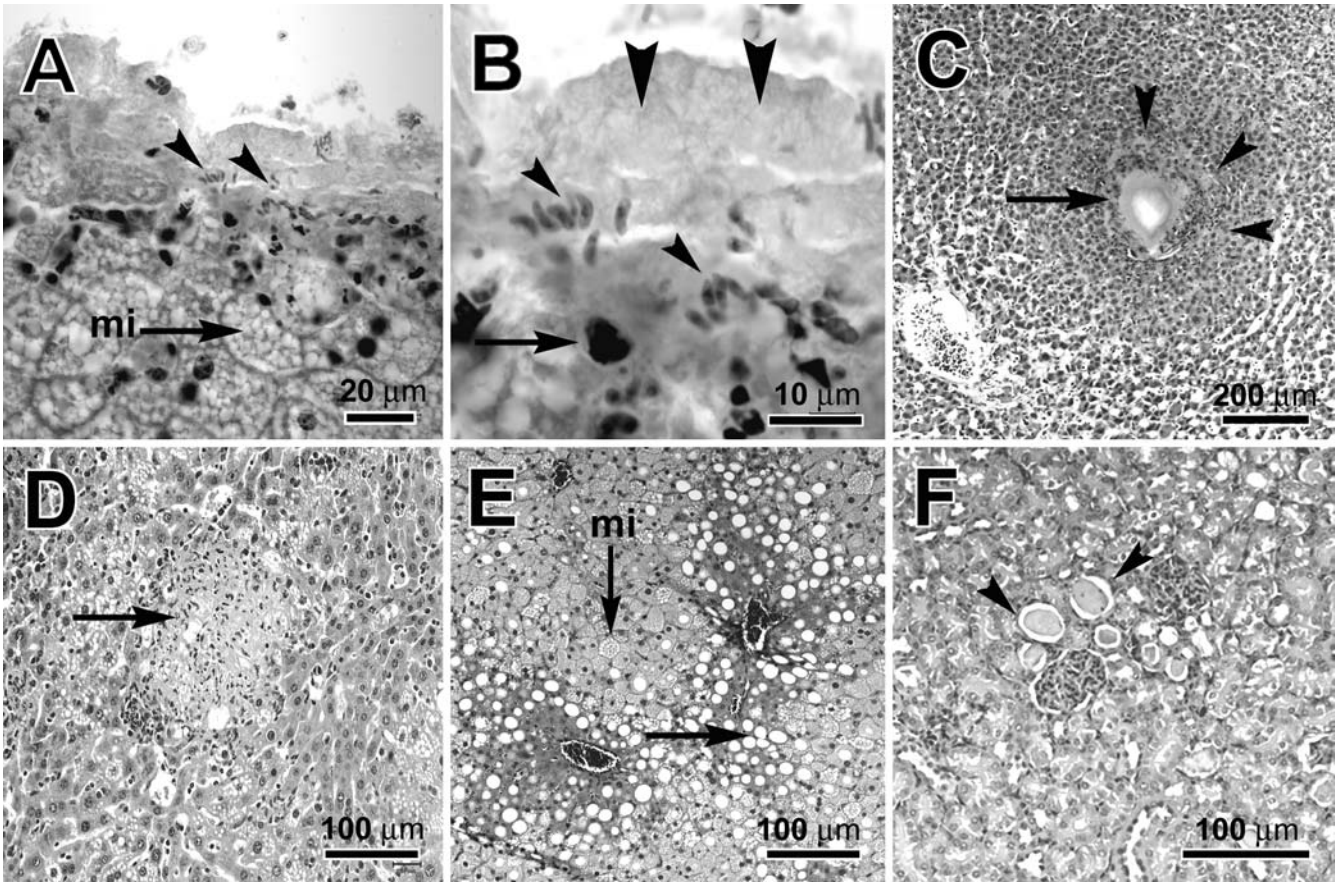

Fig. 2 Lesions of *B. darlingi* in the liver and kidneys of experimentally infected outbred Swiss Webster mice, H and E stain. **A** Liver of a mouse treated with dexamethasone and inoculated with tachyzoites 10 DPI. Note the foamy appearance of the liver cells due to the presence of microvacuoles (*mi*), with tachyzoites (*arrowheads*). **B** Higher magnification showing the characteristic crescent-shaped tachyzoites in the liver capsule (*small arrowheads*), necreotic hepatocyte (*arrow*), and fibrinous capsulitis (*large arrowheads*). **C** Liver of a mouse 70 DPI after I.P. inoculation with bradyzoites. Note granulomatous inflammation (*arrowheads*) surrounding a degenerating tissue cyst (*arrow*). **D** Focal casaetion necrosis in the liver. **E** Severe diffuse hepatic lipidosis with macrovacuolation (*arrow*) and microvacuolation (*mi*). **F** Kidney of a mouse showing the presence of protein casts in the collecting tubules (*arrowheads*)

characterized by macrovacuolar changes in periportal areas and microvacuolar changes in the midzonal and centrolobular areas associated with a few scattered clusters of lymphocytes and megakaryocytes (Fig. 2E). Additionally, mild lymphoplasmacytic infiltrates with few eosinophils were observed in the portal areas. In sections of kidneys, there was a mild multifocal tubular proteinosis and focal necrosis of the tubular epithelium (Fig. 2F). Sections of spleen, brain, and muscles were normal. Sulfadiazine-treated, bradyzoite-infected mice were challenged 2 weeks after the end of the sulfadiazine treatment with $2.5–3\times10^5$ bradyzoites of the same strain (homologous) or a different strain (heterologous) *B. darlingi*. They survived an additional 30–40 days and did not show any clinical signs throughout the entire observation period. Neither parasites nor gross or microscopic lesions were found at autopsies performed at 60 and 70 DPI in these mice. To investigate whether the route of inoculation or the biological diversity of the isolates affected the outcome of infection, mice were inoculated with two different isolates via two different routes. In the dexamethasone-treated mice inoculated with bradyzoites obtained from ear cysts of the first opossum, mice injected intraperitoneally produced a large quantity (>1.5 ml) of peritoneal exudate containing few *B. darlingi* parasites. By contrast, the dexamethasone-treated mice inoculated subcutaneously with bradyzoites obtained from either ear cysts of the first opossum, or liver and lung cysts of the second opossum produced less than 0.5 ml of peritoneal exudate from which *Besnoitia* organisms were absent ($P<0.5$). Intracellular forms (tachyzoites and immature schizonts) were located either directly within the cytoplasm or within vacuoles in peritoneal macrophages. Whether parasites invaded the macrophages or were phagocytized by them is not clear. Most of the intracellular tachyzoites found within peritoneal macrophages were in some stage of division. Occasional extracellular organisms were observed in peritoneal exudates, apparently released by the rupture of infected cells. There were no differences in the clinical manifestations, amount of peritoneal exudates, or in the pathological lesions caused by either of the two isolates.

Phylogenetic position of the parasite isolate

To help corroborate the identity of the parasite as *B. darlingi*, ITS-1 was sequenced from the MIBD1 isolate. This sequence was compared to homologues belonging to related *Besnoitia* species including those of *B. besnoiti*, *B. jellisoni*, *B. oryctofelisi*, and a *B. darlingi* isolate previously reported from Mississippi. Only these congeners possessed ITS-1 sequences similar enough to permit unequivocal alignment with the Michigan isolate. Phylogenetic trees reconstructed from Kimura 2-parameter distances using the neighbor joining algorithm, and optimal trees under maximum parsimony (not shown) each provided strong support for a close relationship between *B. darlingi* isolates from Michigan and Mississippi (Fig. 3).

Discussion

The main objective of the present study was to determine whether dexamethasone treatment could permit the establishment of *B. darlingi* infections in outbred mice in order to study this poorly defined, obligate intracellular apicomplexan parasite. We succeeded in isolating *B. darlingi* from naturally infected opossums and establishing experimental infections in outbred, dexamethasone-treated Swiss Webster albino mice. Intraperitoneal and subcutaneous inoculation of *B. darlingi* bradyzoites into these treated mice resulted in proliferation of parasites within monocytes of the peritoneal fluid, followed by the development of tissue cysts.

To validate this animal model, we evaluated protection against parenteral inoculation of bradyzoite and tachyzoite stages of *B. darlingi* by treating some mice with sufadiazine before and after inoculation. Mice treated with prophylactic doses of sulfadiazine for 12 days were completely protected against primary and challenge infections. In contrast, severe pathology resulted from *B. darlingi* infection in outbred mice treated with dexamethasone in drinking water, regardless of the parasite stage, the route of inoculation or the parasite isolate used. This accelerated pathogenesis is likely due to greater virulence or suppressed host immunity, however, the specific mechanism is unknown. Unlike the macroscopic cysts typically observed in naturally infected opossums, the tissue cysts established in dexamethasone-treated mice were microscopic, suggesting that mice may not serve as natural intermediate hosts of *B. darlingi* (Dubey et al. 2002). However, it is possible that these cysts appeared microscopic simply because they were not yet mature.

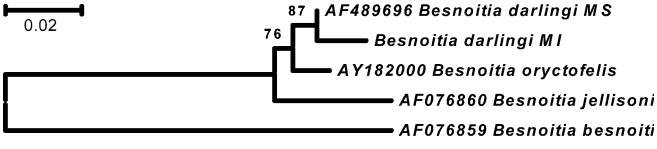

Fig. 3 Midpoint rooted neighbor joining tree of ITS-1 sequences based on 1,000 nonparametric bootstrap replicates using Kimura 2-parameter (K2P) distances

Mice inoculated with culture-derived *B.darlingi* tachyzoites showed a similar pathogenesis to that displayed by mice inoculated with *B. darlingi* bradyzoites isolated originally from opossums, with the following few exceptions. In dexamethasone-treated mice, the onset of severe clinical disease and death was more rapid in those infected by culture-derived tachyzoites than in those infected by bradyzoites (9–10 vs 13–17 DPI). In untreated mice, those infected by tachyzoites showed signs of infection at 18 DPI, whereas those infected by bradyzoites developed chronic infection only, without any apparent clinical signs. These findings suggest that using dexamethasone was necessary to establish *B. darlingi* infection in outbred mice inoculated with bradyzoites, but was unnecessary in mice infected with the tachyzoites. These results corroborate earlier findings underscoring the importance of immunosuppressive agents in inducing murine infection with clinical disease after inoculation with *Neospora caninum* (Darius et al. 2004). Those results along with results reported here suggest that immune suppression may have utility in establishing models of tissue cyst coccidia more generally. This would be valuable, as the vast majority of such parasite taxa have been described only from their natural intermediate hosts, which often do not lend themselves readily to experimental study.

Sulfadiazine may serve as a rationale treatment for animals with besnoitiosis. Because sulfadiazine was also protective in tachyzoite-infected mice in which no clinical signs were observed for up to 50 DPI, its activity was examined against developing *B. darlingi* tachyzoites in BT cell cultures in a separate report (Elsheikha and Mansfield 2004). Sulfadiazine was found to be coccidiocidal at as little as 10 μg/ml. This might be due to a high susceptibility of the tachyzoites to sulfadiazine.

Corticosteroids such as dexamethasone are physiological inhibitors of inflammatory responses and are widely used as anti-inflammatory and immunosuppressive agents in the treatment of many autoimmune and allergic diseases. Some of the mechanisms by which corticosteroids can suppress murine immune responses are to suppress natural killer (NK) cell activity by acting directly on the NK effector cells and/or to inhibit the differentiation and antigen presentation activity of dendritic cells (Cox et al. 1982; Pan et al. 2001). Previous use of corticosteroids in the development of experimental animal models to study coccidian parasitism suggested their applicability for establishing *Besnoitia* infection (Dubey et al. 1974; Boy et al. 1990; Fenger et al. 1997; Cutler et al. 2001). In our study, the high susceptibility of this corticosteroid-treated outbred mouse to *B. darlingi* infection suggests that suppressing immunity or other important host immune factors greatly enhances the susceptibility of mice to this infection. Also, robust immunity may explain the ability of dexametha-

sone-untreated, sulfadiazine-treated mice to eliminate or thwart the bradyzoites progress after repeated exposure. Outbred mice used in this study are resistant to the bradyzoite stage of *B. darlingi* inoculation but highly susceptible to the tachyzoite stage. This paradox in the ability of the bradyzoite and tachyzoite stages to cause an infection in these mice is not surprising. Like other cyst-forming coccidia, bradyzoites of *Besnoitia* spp. are hypobiotic, slowly proliferating and likely to form cysts. This stage survives within the immune-competent host for a long time without inducing clinical signs. As immune competence is impaired (such as during stress), bradyzoites transform into the rapidly proliferating and more virulent tachyzoite stage, which invades the blood circulation and infects various body tissues, causing disease.

In the present study, comparative sequence analysis of the ITS-1 portion of rDNA confirmed the identity of this parasite isolate as *B. darlingi*. Previous phylogenetic analysis of a portion of the Beta subunit of the RNA polymerase (rpoB) gene encoded by the parasite apicoplast genome also supported the designation of the parasite isolated from these opossums as *B. darlingi* (Elsheikha et al. 2004). These data indicate that these *B. darlingi* isolates are genetically similar although from southern and northern parts of the midwestern United States. Also, these data contribute evidence that parasites assigned to this coccidian genus on morphological grounds comprise a monophyletic group. In summary, this work demonstrates that this dexamethasone-treated outbred mouse model is suitable for studying pathogenesis of *B. darlingi*, for obtaining viable isolates of the parasite, and for testing the protective effect of chemotherapeutic drug candidates against infection with *B. darlingi* and possibly other species of this genus.

Acknowledgements We thank Dr. Frances Kennedy from the Diagnostic Center for Population and Animal Health, Michigan State University (MSU) for her kind assistance with pathology and Dr. Shirly Owens from the Center for Advanced Microscopy, MSU for her kind help with illustrations. We also thank Abimbola Odukoyu and Tran Ta for technical help with the PCR and sequencing experiments. This study was performed in accordance to the law and regulations of the United States of America.

References

Boy MG, Galligan DT, Divers TJ (1990) Protozoal encephalomyelitis in horses: 82 cases (1972–1986). J Am Vet Med Assoc 196:632–634

Cox WI, Holbrook NJ, Grasso RJ, Specter S, Friedman H (1982) Suppression of the natural killer cell activity of murine spleen cell cultures by dexamethasone (41489). Proc Soc Exp Biol Med 171:146–150

Cutler TJ, MacKay RJ, Ginn PE, Gillis K, Tanhauser SM, LeRay V, Dame JB, Greiner EC (2001) Immunoconversion against *Sarcocystis neurona* in normal and dexamethasone-treated horses challenged with *S. neurona* sporocysts. Vet Parasitol 95:197–210

Darius AK, Mehlhorn H, Heydorn AO (2004) Effects of toltrazuril and ponazuril on *Hammondia heydorni* (syn. *Neospora caninum*) infections in mice. Parasitol Res 92:520–522

Dubey JP, Davis GW, Koestner A, Kiryu K (1974) Equine encephalomyelitis due to a protozoan parasite resembling *Toxoplasma gondii*. J Am Vet Med Assoc 165:249–255

Dubey JP, Lindsay DS, Rosenthal BM, Sreekumar C, Hill DE, Shen SK, Kwok OCH, Rickard LG, Black SS, Rashmir-Raven A (2002) Establishment of *Besnoitia darlingi* from opossums (*Didelphis virginiana*) in experimental intermediate and definitive hosts, propagation in cell culture, and description of ultrastructural and genetic characteristics. Int J Parasitol 32:1053–1064

Elsheikha HM, Mansfield LS (2004) Determination of the activity of sulfadiazine against *Besnoitia darlingi* tachyzoites in cultured cells. Parasitol Res 93:423–426

Elsheikha HM, Mansfield LS, Fitzgerald SD, Saeed MA (2003) Prevalence and tissue distribution of *Besnoitia darlingi* cysts in the Virginia opossum (*Didelphis virginiana*) in Michigan. Vet Parasitol 115:321–327

Elsheikha HM, Fitzgerald SD, Rosenthal BM, Mansfield LS (2004) Concurrent presence of *Sarcocystis neurona* sporocysts, *Besnoitia darlingi* tissue cysts, and *Sarcocystis inghami* sarcocysts in naturally infected opossums (*Didelphis virginiana*). J Vet Diagn Invest 16:352–356

Fenger CK, Granstrom DE, Gajadhar AA, Williams NM, McCrillis SA, Stamper S, Langemeier JL, Dubey JP (1997) Experimental induction of equine protozoal myeloencephalitis in horses using *Sarcocystis* sp. sporocysts from the opossum (*Didelphis virginiana*). Vet Parasitol 68:199–213

Kumar S, Tamura K, Jakobsen IB, Nei M (2001) MEGA2: Molecular Evolutionary Genetics Analysis software. Arizona State University, Tempe

Pan J, Ju D, Wang Q, Zhang M, Xia D, Zhang L, Yu H, Cao X (2001) Dexamethasone inhibits the antigen presentation of dendritic cells in MHC class II pathway. Immunol Lett 76:153–161

Paperna I, Lainson R (2001) Light microscopical structure and ultrastructure of a *Besnoitia* sp. in the naturally infected lizard *Ameiva ameiva* (Teiidae) from north Brazil, and in experimentally infected mice. Parasitology 123: 247–255

Schneider CR (1976) The distribution of lizard besnoitiosis in Panama, and its transfer to mice. J Protozool 14:674–678

Senaud J, Mehlhorn H, Scholtyseck E (1974) *Besnoitia jellisoni* in macrophages and cysts from experimentally infected laboratory mice. J Protozool 21:715–720

Shkap V, Pipano E, Greenblatt C (1987) Cultivation of *Besnoitia besnoiti* and evaluation of susceptibility of laboratory animals to cultured parasites. Vet Parasitol 23:169–178

Smith DD, Frenkel JK (1977) *Besnoitia darlingi* (Protozoa: Toxoplasmatinae): cyclic transmission by cats. J Parasitol 63:1066–1071

Tanhauser SM, Yowell CA, Cutler TJ, Greiner EC, MacKay RJ, Dame JB (1999) Multiple DNA markers differentiate *Sarcocystis neurona* and *Sarcocystis falcatula*. J Parasitol 85:221–228