AVIAN DISEASES 52:657–664, 2008

Cellular Assessment of Crop Lymphoid Tissue from Specific-Pathogen-Free White Leghorn Chickens After *Salmonella* Enteritidis Challenge

Lara E. Vaughn, Peter S. Holt,[A] and Richard K. Gast

Egg Safety & Quality Research Unit, Russell Research Center, USDA, Agricultural Research Service, 950 College Station Road, Athens, GA 30605

Received 23 May 2008; Accepted and published ahead of print 19 August 2008

SUMMARY. The crop may be an important site along the upper alimentary tract in which a humoral immune response against *Salmonella* Enteritidis (SE) is elicited locally. The mucosal immune response within the crop (ingluvies) of specific-pathogen-free (SPF) white leghorn (WL) chickens against SE was investigated. Three trials were conducted using SPF WL pullets at age 5–6 wk. Trial 1 consisted of 77 birds evaluated for 10 wk post-SE infection (pi), trial 2 was composed of 72 birds monitored through 8 wk pi, and trial 3 was made up of 30 birds assessed for 5 wk pi. Birds were challenged *per os* with 10^8 colony-forming units/ml SE phage type 13. Crop lavage samples, crop tissues, ceca, and/or liver-spleen were collected preinfection and then at weekly intervals post-SE infection. Bacteriologic examination of cecal contents and/or liver-spleen occurred weekly to monitor progression of SE infection. Crop lavages were analyzed for SE-lipopolysaccharide (LPS)-specific immunoglobulin A (IgA) by enzyme-linked immunosorbent assay to assess humoral immune response. General histologic staining (hematoxylin and eosin [H&E] and methyl green-pyronin [MGP]) and immunohistochemical (IHC) staining (monoclonal antibodies CD45 and Bu-1) were applied to serial sections of crop to evaluate lymphoid tissue via light microscopy, to grade isolated lymphoid follicles (ILFs) by using score 0 (minimal, <50 μm in diameter) to score 5 (sizable, >200 μm in diameter) scale, and to characterize the cellular population of ILFs. Results revealed that cecum samples and liver-spleen samples were 100% SE culture positive at 1 wk pi, and then the percentage of SE positives progressively declined over time. Markedly increased crop SE-LPS-specific IgA antibodies were detected in crop samples by 2–3 wk pi, and the humoral response remained elevated above week 0 baseline for the duration of each trial. Crop ILFs of score 3 to 5 were observed in H&E-stained tissues, with an increased proportion of ILFs in post-SE–infected crops *vs.* uninfected. MGP staining showed plasma cells scattered within and at the periphery of ILFs. IHC staining revealed CD45 (pan-leukocyte) and Bu-1 (B-lymphocyte)–positive cells within crop ILFs. The chicken crop seems to be an organ in which lymphoid tissue may arise in response to enteric SE infection, and a site in which a humoral response may be generated against the SE pathogen.

RESUMEN. Evaluación celular del tejido linfoide del buche de aves leghorn blancas libres de patógenos específicos.

El buche es un sitio importante del tracto digestivo superior donde la respuesta inmune humoral contra *Salmonella* Enteritidis se estimula localmente. En este estudio se investigó la respuesta inmune mucosal dentro del buche de aves leghorn blancas libres de patógenos específicos (SPF, por su sigla en inglés). Tres ensayos fueron llevados a cabo usando pollonas leghorn blancas SPF de 5–6 semanas de edad. En el primer ensayo se evaluaron 77 aves post infección con *Salmonella* Enteritidis durante 10 semanas. En el segundo ensayo re realizó seguimiento a 72 aves durante 8 semanas postinfección, y en el ensayo 3 se evaluaron 30 aves hasta 5 semanas postinfección. Las aves fueron desafiadas individualmente con 10^8 unidades formadoras de colonia /ml de *Salmonella* Enteritidis, fagotipo 13. Muestras de lavado de buche, tejidos de buche, ciego y/o hígado-bazo fueron tomadas preinfecciòn y luego con intervalos semanales postinfección con *Salmonella* Enteritidis. La evaluación bacteriológica del contenido cecal y/o del hígado-bazo se realizó semanalmente para evaluar la progresión de la infección con *Salmonella* Enteritidis. Para evaluar la respuesta inmune, los lavados de buche fueron analizados mediante Ensayo de inmunoabsorbancia ligada a enzimas para determinar la presencia de lipopolisacáridos de *Salmonella* Enteritidis, específicos para inmunoglobulina A (IgA). Se realizaron coloraciones histológicas (hematoxilina-eosina, verde metal pironina e inmunohistoquímica con anticuerpos monoclonales CD45 y Bu-1) de secciones seriadas de buche para evaluar el tejido linfoide usando microscopía de luz, para calificar los folículos linfoides aislados usando una escala de calificación de 0 (mínima, <50 μm en diámetro) a 5 (tamaño menor de, >200 μm en diámetro), y caracterizando la población celular de los folículos linfoides aislados. Los resultados revelaron que las muestras de ciego e hígado/bazo fueron 100% positivas a *Salmonella* Enteritidis una semana postinfección y el porcentaje de positividad fue disminuyendo progresivamente a través del tiempo. Se observó un incremento marcado de anticuerpos, IgA específica para lipopolisacáridos de *Salmonella* Enteritidis, en las muestras de buche de 2–3 semanas postinfección y la respuesta humoral permaneció elevada por encima de la línea base determinada para la semana 0 durante la realización de cada ensayo. En los tejidos teñidos con hematoxilina eosina se observó una calificación de 3 a 5 en los folículos linfoides aislados, con incremento en su proporción postinfección con *Salmonella* Enteritidis, comparada con las aves no infectadas. La coloración con verde metil pironina mostró células plasmáticas escasas dentro y en la periferia de los folículos linfoides aislados. La prueba de inmunohistoquímica mostró células positivas a CD45 (pan - leucocitos) y Bu-1 (linfocitos B) dentro de los folículos linfoides aislados del buche. El buche de los pollos parece ser un órgano en el cual el tejido linfoide aumenta en respuesta a la infección por *Salmonella* Enteritidis y un sitio en el cual la respuesta inmune humoral puede ser generada contra *Salmonella* Enteritidis patógena.

Key words: *Salmonella* Enteritidis, chicken, crop, mucosal immune system, IgA, gut-associated lymphoid tissue, isolated lymphoid follicles, immunohistochemistry

Abbreviations: ANOVA = analysis of variance; AP = alkaline phosphatase; BG = brilliant green agar; CFU = colony-forming units; DAB = diaminobenzidine; ELISA = enzyme-linked immunosorbent assay; GALT = gut-associated lymphoid tissue; H&E = hematoxylin and eosin; HRP = horseradish peroxidase; Ig = immunoglobulin; IHC = immunohistochemistry/immunohistochemical; ILF = isolated lymphoid follicle; LPS = lipopolysaccharide; MGP = methyl green-pyronin; NA = nalidixic acid; nalR = nalidixic-acid resistant; NB = novobiocin; OD = optical density; PBS = phosphate-buffered saline; PP = Peyer's patch; PT13 = phage type 13; PBS = phosphate-buffered saline; pi = postinfection; RV = Rappaport-Vassiliadis; SE = *Salmonella* Enteritidis; SEPRL = Southeast Poultry Research Laboratory; SPF = specific-pathogen-free; TBS = Tris-buffered saline; TSB = tryptic soy broth; WL = white leghorn

[A]Corresponding author. E-mail: pete.holt@ars.usda.gov

The chicken crop, ingluvies, seems to have the functional capacity to produce a mucosal immune response against *Salmonella enterica* serovar Enteritidis (10,13,27,28,30). A humoral immune response against *Salmonella* Enteritidis (SE) has been detected within the crop of specific-pathogen-free (SPF) white leghorn (WL) hens and commercial egg-layer strains of chickens after *per os* experimental SE challenge (27,28,30). SE-lipopolysaccharide (LPS)–specific immunoglobulin (Ig) A humoral response in crop lavage samples was detectable by enzyme-linked immunosorbent assay (ELISA) at 1 wk postinfection (pi), with an elevated SE-LPS–specific response generated by 2–3 wk pi (10,12,13,27,28). Microscopic examination of hematoxylin and eosin (H&E)-stained crop tissues from post-SE–challenged hens revealed tentative sites of lymphoid aggregations in the crop lamina propria (13,30).

Presumptive lymphoid tissue aggregations and/or isolated lymphoid follicles (ILFs) within SE-infected chicken crops were identified by routine histologic H&E stain and microscopy (10,13,30). However, cellular characterization of the speculative isolated lymphoid follicles of the chicken crop has not been performed. Immunohistochemical (IHC) staining and flow cytometric studies have not been conducted to definitively identify lymphoid-lymphocytic cellular populations. The sites observed by H&E stain seemed to be similar in structure to the ILFs identified by Hamada *et al.* (8) along the murine small intestine. Hamada *et al.* (8) identified lymphoid clusters on the antimesenteric wall of the mouse small intestine, and these ILFs were filled with B220+ cells (B lymphocytes). The murine ILFs were smaller than B-lymphocyte–enriched follicle units of Peyer's patch (PP) and lacked the interfollicular PP regions that contain mainly T cells (8). ILFs of the murine small intestine have also been shown by Lorenz *et al.* (20,21) to contain predominantly B-2 B lymphocytes. Additionally, formation of ILFs along the murine small intestine seemed to occur *de novo* in response to luminal stimuli (8,9,20,21), and mice possessing ILFs had increased production of antigen-specific IgA when orally challenged with *Salmonella* Typhimurium (21). The ILFs of the chicken crop might perhaps be comparable with ILFs of the mouse small intestine identified by Hamada *et al.* (8) and Lorenz *et al.* (20,21), or similar to ILFs of the rat small intestine detected by Hitotsumatsu *et al.* (9).

The chicken crop seems to be an organ of importance in the study of gut-associated lymphoid tissue (GALT) and mucosal immunity. The present study sought to definitively determine the presence of lymphoid tissue within the crop of SPF chickens after SE infection and to investigate the SE-LPS–specific IgA mucosal immune response of the crop through 10 wk pi, 8 wk pi, and 5 wk pi, in three separate trials, respectively. Objectives were to monitor persistence of SE in cecum and evaluate SE dissemination to liver and spleen, to compare temporal evolution of SE-specific IgA humoral response in the crop after SE exposure, and to assess crop sections from SE-infected birds for presence of ILFs and identify ILF cellular populations by histologic and IHC staining.

MATERIALS AND METHODS

Animals. Three trials were conducted with SPF WL chickens, approximately 5–6 wk of age, obtained from the flock maintained by Southeast Poultry Research Laboratory (SEPRL), USDA–Agricultural Research Service, Athens, GA. Trial 1 consisted of 77 birds, trial 2 was made up of 72 birds, and trial 3 was made up of 30 birds. For each trial, birds were housed within a climate-controlled biosafety level-2 building in which birds were placed within multiple brooder cages and allowed access to antibiotic-free feed and water *ad libitum*.

Bacterial strain. SE phage type 13 (PT13) was selected for experimental challenge of birds (6). Frozen stock maintained at −70 C of nalidixic acid-resistant (nalR) SE PT13 (strain SE89-8312) was thawed and cultured on nutrient agar at 37 C for 18 hr. Isolated colonies were subcultured on brilliant green (BG) agar containing 20 μg/ml novobiocin (NB) and 20 μg/ml nalidixic acid (NA) to ensure conserved nalidixic acid resistance. The nalR SE PT13 culture was further cultivated in 10 ml of tryptic soy broth at 37 C for 18 hr, and then the broth culture was diluted in sterile physiological saline to prepare 10^8 colony-forming units (CFU)/ml inoculum for experimental infection of birds.

Experimental design. Studies conducted were approved by and in accordance with guidelines of the SEPRL Institutional Animal Care and Use Committee. *Salmonella*-free status of chickens was determined before commencement of the experiment. A 1.0-g weight of feces was collected by placement of sterile catch trays under birds, and feces were selectively enriched in Rappaport-Vassiliadis (RV) broth for 24 hr at 37 C–42 C, and then streak plated onto BG agar containing 20 μg/ml NB. *Salmonella* was not detectable in fecal cultures.

Three separate trials were set up to ensure reproducibility of research findings. The three trials were conducted using SPF WL pullets at 5–6 wk of age, and birds were challenged *per os* with 10^8 CFU/ml SE nalR PT13. Trial 1 consisted of 77 birds that were evaluated from week 0 preinfection to 10 wk after SE infection (postinfection [pi]); trial 2 was made up of 72 birds that were monitored from week 0 through 8 wk pi; and trial 3 was made up of 30 birds that were assessed from week 0 to 5 wk pi. Crop lavage samples, crop tissues, ceca, internal organs, or a combination were collected at week 0 preinfection and then collected at weekly intervals post-SE infection. During week 0 preinfection for trials 1–3, crop lavages were performed on SPF WL chickens to establish baseline crop IgA by ELISA. The chickens were then euthanized via CO_2 gas inhalation, and the crop organ was harvested from each bird for histopathology assessment of lymphoid tissue at week 0 preinfection. After chickens were challenged *per os* with SE nalR PT13, crop lavage samples, crop tissues, cecal contents, liver-spleen samples or a combination were collected weekly. Bacteriologic examinations of cecal contents, liver-spleen samples, or both were conducted weekly to monitor progression of SE infection. Crop lavage samples were analyzed for SE-LPS–specific IgA by ELISA. General histologic and IHC staining techniques were applied to crop tissue serial sections to identify lymphoid tissue and to determine cellular populations of the ILFs via light microscopy. H&E-stained crop sections were selected to grade lymphoid tissue by using the score 0 (minimal, <50 μm in diameter) to score 5 (sizable, >200 μm in diameter) scale developed by Vaughn *et al.* (30).

Bacteriologic examination. Bacterial culture for SE nalR PT13 was performed on cecum samples collected at weekly intervals post-SE infection for trials 1, 2, and 3. Liver and spleen organ samples were harvested weekly post-SE infection for trial 1 and trial 3 for bacterial culture of SE nalR PT13. One cecum (mid-cecum to cecal apex) per bird was aseptically harvested immediately postmortem. Cecum samples of 1.0-g weight were placed into sterile whirl-pack bags (Fisher Scientific, Suwanee, GA) and RV broth was added at 9 times volume/tissue weight, and then ceca were macerated in a stomacher for 30 sec to evacuate cecal contents. A 2.0- × 2.0-cm portion of right liver lobe and the entire spleen were aseptically harvested, and liver-spleen was combined in whirl-pack bags. Then, RV broth 9 times volume/tissue weight was added, and organs were macerated for 30 sec in a stomacher. A 100-μl portion from each macerated cecum and liver-spleen sample was directly spread-plated onto BG agar containing 20 μg/ml NB and 20 μg/ml NA. The BG + NB + NA direct spread plates and RV samples were incubated at 37 C overnight. Plates were then assessed for SE colony growth. In instances where direct plating resulted in no growth, the RV-enriched samples were streaked onto BG + NB + NA agar and streak plates were incubated 24 hr at 37 C and then assessed for typical SE colony growth. Questionable colonies were further differentiated based on biochemical tests using triple sugar iron agar and modified-lysine iron agar slant tubes, and agglutination reaction with antiserum against *Salmonella* serogroup D_1 somatic antigen (Beckton Dickinson-

Difco, Bedford, MA). Cecum and liver-spleen samples were recorded as positive if SE was recoverable either by direct plating or after selective RV-enrichment. Samples with no SE growth detectable either by direct plating or after RV-enrichment were deemed as negative.

Crop lavage sample collection. Crop lavages were performed in a similar manner to the protocol followed by Holt *et al.* (13) and Vaughn *et al.* (30). Briefly, 5 ml of sterile glycine solution was slowly infused into the crop, the fluid sample was immediately aspirated back into the syringe, and then the crop lavage aspirate was dispensed from syringe to a sterile collection container. The lavage procedure was repeated per individual bird using a fresh lavage device and separate sample collection container. A 1.5–2.0-ml portion from each neat crop lavage sample was centrifuged at 10,000 rpm for 5 min to remove feed particulate debris and excess mucous. The supernatant fraction was collected and stored at −20 C.

Crop SE-specific IgA ELISA. The crop lavage samples obtained at weekly time points after SE infection were analyzed by ELISA for SE-LPS–specific IgA as described previously by Holt *et al.* (11,12,13) and Vaughn *et al.* (30). Crop supernatant samples at 1:2 dilutions were assessed by ELISA, and the optical density (OD) values were obtained at 405-nm wavelength using a Multiskan Ascent (Thermo Fisher Scientific, Waltham, MA) microplate photometer. The OD values represented the level of IgA specific against SE-LPS in each crop lavage sample.

Crop histology and lymphoid tissue scoring. Preinfection week 0 and at weekly time points after SE-infection, chickens were euthanized via CO_2 gas inhalation, and immediately postmortem the entire crop with 1.0 inch (2.54 cm) of attached esophagus was excised. Tissues were fixed intact in 10% neutral buffered formalin for 24 hr, and the crops were then sectioned through the midbody region. The plane of the cut passed through the entirety of the hollow-bodied crop organ to produce ring-shaped circular sections. One to two tissue sections per crop were inserted into standard histology tissue cassettes (Thermo Fisher Scientific), routinely processed, paraffin embedded, microtome cut, and affixed to glass slides. Crop tissue slides were stained with H&E, and then they were examined via light microscopy. The H&E-stained crop tissues were evaluated full-circle for the presence of lymphoid aggregations in the epithelium and lamina propria. All apparent ILFs were graded using the score 0 (minimal, <50 μm in diameter) to score 5 (sizable, >200 μm in diameter) scale that was established by Vaughn *et al.* (30). An ocular grid reticle (Thermo Fisher Scientific) was used to make the score determinations at 200× magnification. Scores 3 to 5 denote the ILFs that were well organized, of moderate (score 3) to heightened (score 5) cellularity, and of increased size. Isolated lymphoid follicles within the score 3 to 5 range were selected to make crop lymphoid tissue comparisons between SE-infected chickens and uninfected control chickens.

Monoclonal antibodies. Monoclonal antibodies used for immunohistochemical staining were mouse anti-chicken CD45 (pan-leukocyte) unlabeled as the primary antibody (Southern Biotechnology Associates, Birmingham, AL) at working concentration 50 μg/ml and goat anti-mouse IgM conjugated with alkaline phosphatase (AP) enzyme as secondary antibody (Calbiochem, San Diego, CA) at 50 μg/ml; and mouse anti-chicken Bu-1 (B lymphocyte) unlabeled as primary antibody (Southern Biotechnology Associates) at concentration 50 μg/ml and goat anti-mouse IgG labeled with horseradish peroxidase (HRP) enzyme as secondary antibody (Calbiochem) at 1:50 dilution.

General histologic and immunohistochemical staining. Optimal staining conditions were determined using tissue slides prepared from a multiple-tissue block that contained formalin-fixed, paraffin-embedded 6-mm biopsy sections of gastrocnemius muscle, thymus, bursa of Fabricius, spleen, liver, crop, proventriculus, PP, and cecal tonsil from normal/healthy, uninfected chickens. The multiple-tissue slides were included as staining controls during the staining of each group of crop tissue slides. Replicate tissue cuts 3–5 μm in thickness were made from paraffin-embedded crop tissue blocks from the uninfected controls and from SE-infected chickens. Tissues were mounted on positive-charged slides (Thermo Fisher Scientific). Crop slide tissues were deparaffinized with EZ-DeWax solution (BioGenex, San Ramon, CA) and washed in three changes of deionized water. For general histologic staining to visualize plasma cells, a methyl green-pyronin (MGP) solution (Sigma-Aldrich, St. Louis, MO) was used according to the manufacturer's instructions to identify pyroninophilic cells indicative of plasma cells (18,19,26). For the IHC staining of crop tissue slides, a heat-induced epitope retrieval method was used after deparaffinization (4,14). Slides for IHC were immersed in antigen retrieval buffer 0.01 M Tris-base/0.001 M EDTA disodium salt, placed inside a microwave pressure cooker (BioGenex), and then microwave heated at 40–50% power for 3–5 min. Slides were then allowed to cool in Tris/EDTA antigen retrieval buffer for 20–30 min at room temperature. When appropriate, 3% H_2O_2 was applied to slides for 5 min to quench endogenous peroxidases in tissues. All slides were rinsed in deionized water for 5 min. IHC staining to identify aggregations of leukocytes in crop tissue slides was accomplished using mouse anti-chicken CD45 (Southern Biotechnology Associates) pan-leukocyte primary monoclonal antibody, AP-conjugated goat anti-mouse IgM (Calbiochem) as secondary enzyme-conjugated antibody, and fast red substrate (BioGenex). IHC staining to identify B lymphocytes was conducted using mouse anti-chicken Bu-1 (Southern Biotechnology Associates) primary monoclonal antibody, HRP-conjugated goat anti-mouse IgG (Calbiochem) as secondary enzyme-labeled antibody, and diaminobenzidine (DAB) substrate (BioGenex). In brief, steps of the IHC staining process involved application of appropriate primary monoclonal antibody, mouse anti-chicken CD45 or mouse anti-chicken Bu-1, and slides were incubated at 4 C overnight inside a humidified chamber. Slides were then washed for 5 min in Tris-buffered saline (TBS) or phosphate-buffered saline (PBS) to remove unbound excess antibody from tissues. Appropriate enzyme-labeled secondary antibody, goat anti-mouse AP or goat anti-mouse HRP, was applied, and slides incubated 45–60 min at room temperature. Then, slides were washed for 5 min in TBS or PBS to remove any unbound secondary enzyme-conjugated antibody. After washing, bound antibody was detected in crop tissue sections by application of fast red or DAB chromogen-substrate solution (BioGenex) according to manufacturer's instructions, and slides were incubated 5–10 min at room temperature. Slides were washed in deionized water to stop the enzyme-chromogen reaction, and then slides were counterstained with Mayer's hematoxylin (BioGenex). All slides were coverslipped and examined using light microscopy.

Statistical analyses. Statistical analyses were performed using GraphPad Instat (GraphPad Software Inc., San Diego, CA). For bacterial culture results and ELISA data, analysis of variance (ANOVA) with Dunnett's multiple comparison test procedure was conducted to determine statistically significant differences ($P < 0.05$) between controls (week 0 uninfected) *vs.* post-SE infection time points. Kruskal-Wallis nonparametric ANOVA with Dunn's multiple comparison posttest were performed on crop lymphoid tissue score data to assess whether or not statistical differences ($P < 0.05$) existed between uninfected controls and SE-infected bird groups.

RESULTS

Bacterial culture. Cecum samples cultured in trials 1, 2, and 3 revealed recoverable SE postinfection (Figs. 1–3). SE was detected in 100% of cecum samples cultured at 1 wk pi from trials 1, 2, and 3. For all three trials, there was a progressive decline in SE prevalence at 2 wk pi (average 74%) and at 3 wk pi (average 31%). Between 4 wk pi until the end point of each trial, there was a wax and wane pattern of SE culture-positive cecum samples that ranged from no detectable SE (trial 1 at 4 wk pi; trial 3 at 10 wk pi) to 75% (trial 2 at 4 wk pi). SE persisted in trials 1–3 for an extended duration, because SE was recoverable from cecum samples at 9 wk pi in trial 1, at 8 wk pi in trial 2, and at 5 wk pi in trial 3.

SE dissemination to internal organs did occur in trial 1 and trial 3 chickens (Figs. 1, 3). Liver-spleen samples from trial 1 and trial 3 were 100% SE culture positive at 1 wk pi. SE prevalence diminished to 29% at 2 wk pi in trial 1; yet, it remained 100% at 2 wk pi in

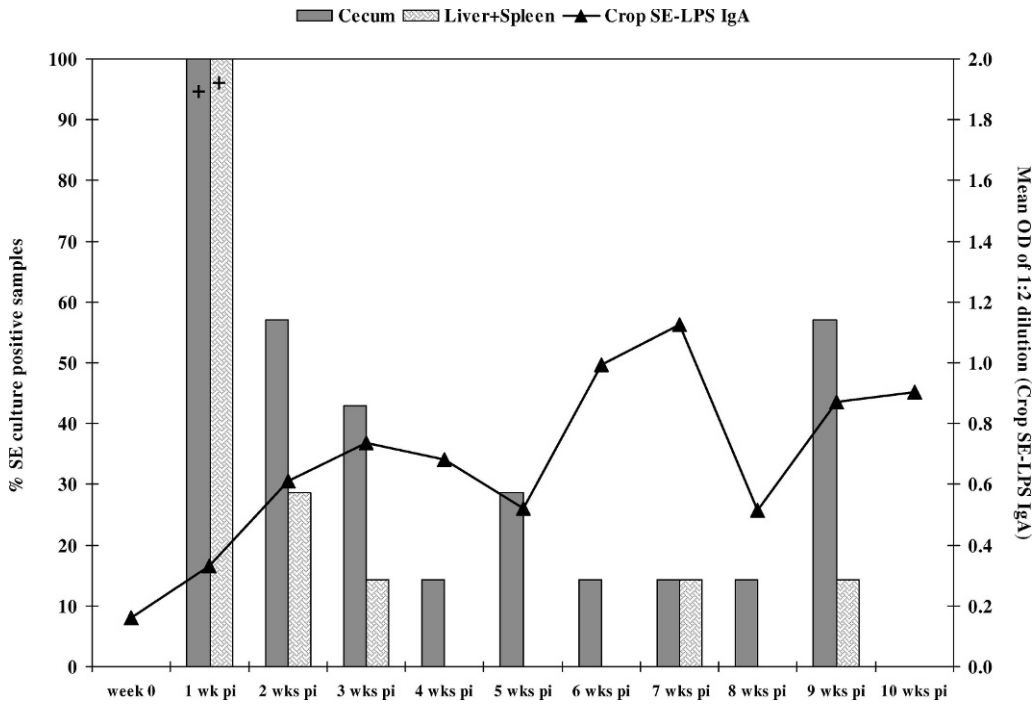

Fig. 1. (Trial 1) Percentage of *Salmonella* Enteritidis (SE) culture-positive cecum samples and SE culture-positive liver-spleen organ samples at weekly intervals from specific-pathogen-free (SPF) white leghorn chickens after SE infection (postinfection [pi]). Enzyme-linked immunosorbent assay analyses of SE-lipopolysaccharide (LPS)-specific immunoglobulin (Ig) A in crop lavage samples from SPF WL chickens after SE infection (pi). Mean optical density values are representative of SE-LPS–specific IgA detected in 1:2 dilution crop lavage supernatant samples at week 0 preinfection and then at weekly intervals post-SE infection. Different birds ($n = 7$) were sampled at each of the weekly time points. A plus sign, +, assigned to a column indicates a significant difference ($P < 0.05$) from the week 0 uninfected control. An asterisk, *, at a line graph value point indicates a significant difference ($P < 0.05$) from the week 0 uninfected control. No asterisk assigned to the line graph denotes that there were no significant differences ($P > 0.05$) from the week 0 control.

trial 3. Overall, the percentage of SE-positive samples declined during the period from 1 wk pi to 4 wk pi. No SE was detectable from liver-spleen samples at 4 wk pi and 5 wk pi in trial 3, and at 4 wk pi to 6 wk pi in trial 1. However, as trial 1 continued through 10 wk pi, a reemergence of SE occurred at 7 wk pi and at 9 wk pi with 14% of liver-spleen samples SE culture positive.

Crop SE-LPS–specific IgA. ELISA demonstrated an increased SE-LPS–specific IgA humoral response in crop lavage supernatant samples from post-SE infection chickens in trial 1, trial 2, and trial 3 (Figs. 1–3). A similar relative pattern of SE-LPS–specific IgA response within the chicken crop was observed in all three trials after SE infection. Before infection at week 0, the SE-LPS–specific IgA levels were minimal. After oral SE challenge, the SE-LPS–specific IgA response was elevated above week 0 in the weekly post-SE infection samples. A markedly increased SE-LPS–specific IgA response was detected between week 0 preinfection and approximately 2–3 wk pi. For the sampling time points closest to SE challenge, a more exaggerated SE-LPS–specific IgA humoral response was noted; however, as time lengthened from the initial SE challenge, a progressive wane of SE-LPS–specific IgA within the crop occurred.

Crop histology and lymphoid tissue scores. Microscopy evaluation of H&E-stained sections of the crop revealed foci of presumptive lymphoid cells in the lamina propria. The isolated lymphoid follicles within score 3 to score 5 range were used for comparisons. The calculated mean (average) of crop lymphoid tissue in score 3–5 range at week 0 (preinfection controls) and at weekly time points post-SE infection for trials 1, 2, and 3 are shown in Fig. 4. An increase of lymphoid tissue in crop sections from SE-infected compared with week 0 controls was determined by comparison of the mean number of score 3–5 range ILFs. Overall, the crop sections from SE-infected chickens compared with uninfected controls had from 2.07- to 4.92-fold increase in isolated lymphoid follicles of score 3–5 range. At 5 wk pi to 10 wk pi, there were significant differences ($P < 0.05$) observed in crop lymphoid tissue within the crops of post-SE infection birds compared with the preinfection controls (Fig. 4). The H&E-stained crop sections evaluated from uninfected control chickens contained some lymphoid tissue areas that were judged as score 3, 4, and 5. However, examination of H&E-stained crop sections from post-SE–infected chickens found an increased number of score 3 to score 5 ILFs in the SE-infected compared with the uninfected controls (Fig. 4).

General histologic and IHC staining. The presumptive H&E-stained isolated lymphoid follicles (Fig. 5A) observed within crop lamina propria were further assessed by IHC staining. IHC staining performed on replicate crop tissue sections from the SE-infected chickens detected a generalized positive cell staining for CD45 pan-leukocytes within the isolated lymphoid follicles (Fig. 5B). Additionally, the ILFs were shown to consist primarily of B lymphocytes stained positive for Bu-1 (Fig. 5C). The MGP staining method detected plasma cells scattered throughout the ILFs and at the periphery of ILFs (Fig. 5D).

DISCUSSION

The mucosal immune system of the avian includes the secondary or peripheral lymphoid tissues of the respiratory, urogenital, and gastrointestinal tracts. Mucosal lymphoid tissue of the alimentary

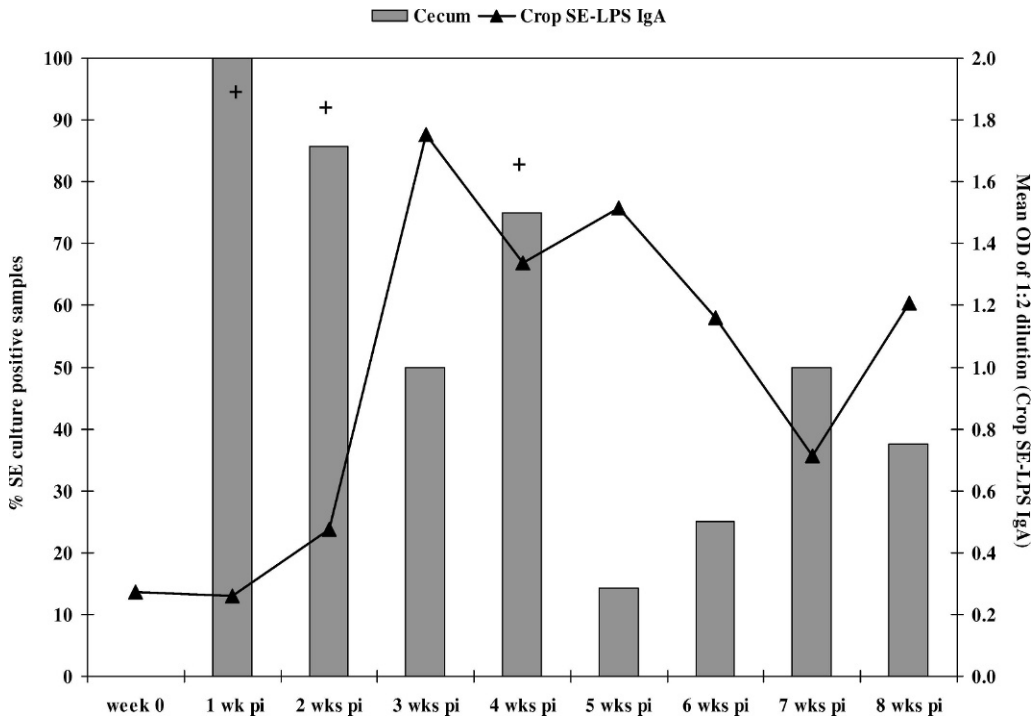

Fig. 2. (Trial 2) Percentage of *Salmonella* Enteritidis (SE) culture-positive cecum samples at weekly intervals from specific-pathogen-free (SPF) white leghorn (WL) chickens post-SE infection (pi). Enzyme-linked immunosorbent assay analyses of SE-LPS–specific immunoglobulin A (IgA) in crop lavage samples from SPF WL chickens after SE infection (pi). Mean optical density values are representative of SE-LPS–specific IgA detected in 1:2 dilution crop lavage supernatant samples at week 0 preinfection and then at weekly intervals post-SE infection. Different birds ($n = 8$) were sampled at each of the weekly time points. A plus sign, +, assigned to a column indicates a significant difference ($P < 0.05$) from the week 0 uninfected control. An asterisk, *, at a line graph value point indicates a significant difference ($P < 0.05$) from the week 0 uninfected control. No asterisk assigned to the line graph denotes that there were no significant differences ($P > 0.05$) from control.

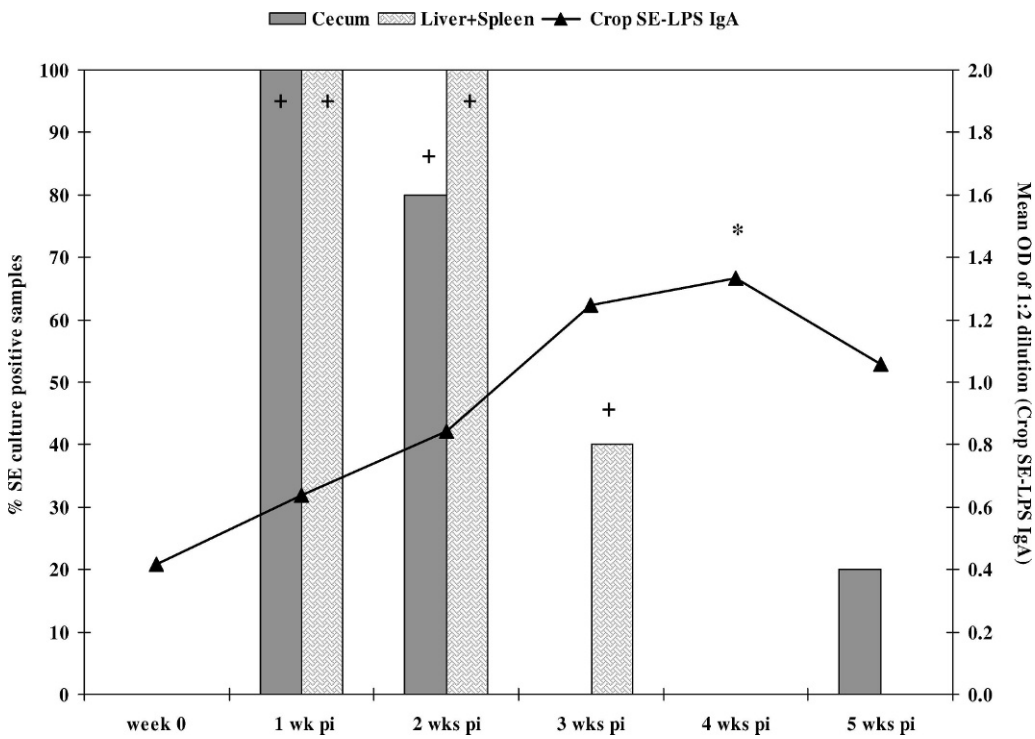

Fig. 3. (Trial 3) The percentage of *Salmonella* Enteritidis (SE) culture-positive cecum samples and percentage of SE culture-positive liver-spleen organ samples at weekly intervals for specific-pathogen-free (SPF) white leghorn (WL) chickens post-SE infection (pi). Enzyme-linked immunosorbent assay analyses of SE-LPS–specific IgA in crop lavage samples from SPF WL chickens after SE infection (pi). Mean optical density values are representative of SE-LPS–specific IgA detected in 1:2 dilution crop lavage supernatant samples at week 0 preinfection and then at weekly intervals post-SE infection. Different birds ($n = 5$) were sampled at each of the weekly time points. A plus sign, +, assigned to a column indicates a significant difference ($P < 0.05$) from the week 0 uninfected control. An asterisk, *, at a line graph value point indicates a significant difference ($P < 0.05$) from the week 0 uninfected control.

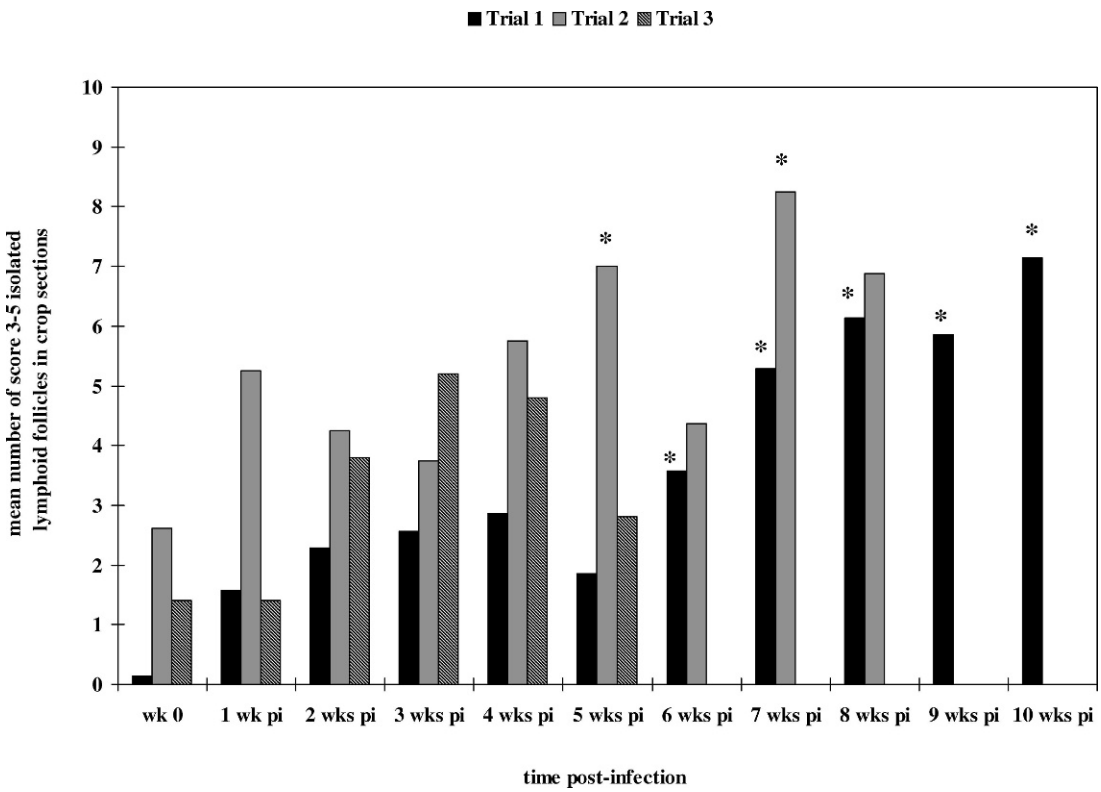

Fig. 4. Average number of score 3–5 isolated lymphoid follicles assessed by light microscopy in hematoxylin and eosin-stained crop sections prepared from specific-pathogen-free white leghorn chickens: trial 1 preinfection week 0 (control) through 10 wk post-*Salmonella* Enteritidis (SE) infection; trial 2 preinfection week 0 (control) through 8 wk post-SE infection; and trial 3 preinfection week 0 (control) through 5 wk post-SE infection. An asterisk, *, above a column indicates a significant difference ($P < 0.05$) in the post-SE-infection (pi) value compared with the week 0 uninfected control value.

tract, known as GALT, is equipped with a cellular repertoire necessary to sample luminal antigens and to provide protective humoral responses (i.e., secretory IgA), cell-mediated responses, or both against microorganisms at mucosal surfaces (15,23). Locations where GALT has been identified in the chicken are the oropharynx, esophagus-proventriculus junction, Meckel's vitelline diverticulum, ileal Peyer's patches, and cecal tonsils (1,2,7,17,24,25).

The crop, situated within the upper gastrointestinal tract, would seem to be a prospective location for gut-associated lymphoid tissue or for tertiary lymphoid tissue to arise in response to bacterial pathogens harbored within the crop or to agents that traverse the crop on descent to the lower alimentary tract. The observation of a greater proportion of lymphoid tissue (ILFs) in crop sections from SE-infected *vs.* uninfected week 0 control chickens (Fig. 4) would seem to be related to the introduction of SE and the antigenic stimulus evoked by the enteroinvasive pathogen. Research data presented in the current study, and by Holt *et al.* (10,13), Seo *et al.* (27,28), and Vaughn *et al.* (30) support the notion that the chicken crop is a location in which GALT, tertiary *de novo* lymphoid tissue, or both can be found in the upper alimentary tract.

IHC and general histologic staining techniques applied to the crop ILFs identified CD45, Bu-1, and pyroninophilic-positive cells that were indicative of leukocytes, B lymphocytes, and plasma cells, respectively (Fig. 5, B–D). The CD45 pan-leukocyte stain confirmed the presence of lymphoid tissue at the sites that were identified previously as ILFs by cursory examination of H&E-stained crop tissue sections (13,30). A predominance of B lymphocytes (Bu-1+ cells) made up the crop ILFs. The MGP staining technique applied to crop sections revealed scattered pyroninophilic cells (plasma cells) within and at the periphery of the ILFs.

Exposure of the gut to enteroinvasive pathogenic bacteria may promote expansion of existent secondary GALT, and the genesis of tertiary lymphoid tissue (5). The lymphoid tissue identified in the chicken crop might perhaps be comparable with the ILFs of the murine small intestine described by Hamada *et al.* (8) and Lorenz *et al.* (20,21). The ILFs of the chicken crop consisted of a predominance of B lymphocytes (Bu-1+ cells), and this finding was similar to the B-lymphocyte staining outcome of ILFs along the murine small intestine. Hamada *et al.* (8) identified lymphoid clusters filled with B lymphocytes (B220+ cells) distributed throughout the antimesenteric mucosa of the mouse small intestine. The ILFs observed by Hamada *et al.* (8) along the antimesenteric wall of the murine small intestine were structurally and functionally similar to follicular units that compose PP; however, the small intestine ILFs were smaller than B cell-enriched follicular units of PP and the ILFs lacked the T-cell–enriched interfollicular regions that are a component of PP. Hamada *et al.* (8) proposed that ILFs of the mouse small intestine were tertiary lymphoid tissue with *de novo* formation. Tertiary lymphoid tissues arise from lymphoid neogenesis, a process thought to perhaps be inducible by antigen or driven by the expression of cytokines, lymphoid chemokines, or a combination (8,9,21,22,29). A portion of the lymphoid tissue observed in H&E-stained crop sections from SE-challenged chickens may be tertiary lymphoid tissue that developed *de novo* subsequent to SE infection. The finding of a slight amount of lymphoid tissue present in the crop of uninfected control chickens could perhaps be considered a relatively normal observation, because chickens

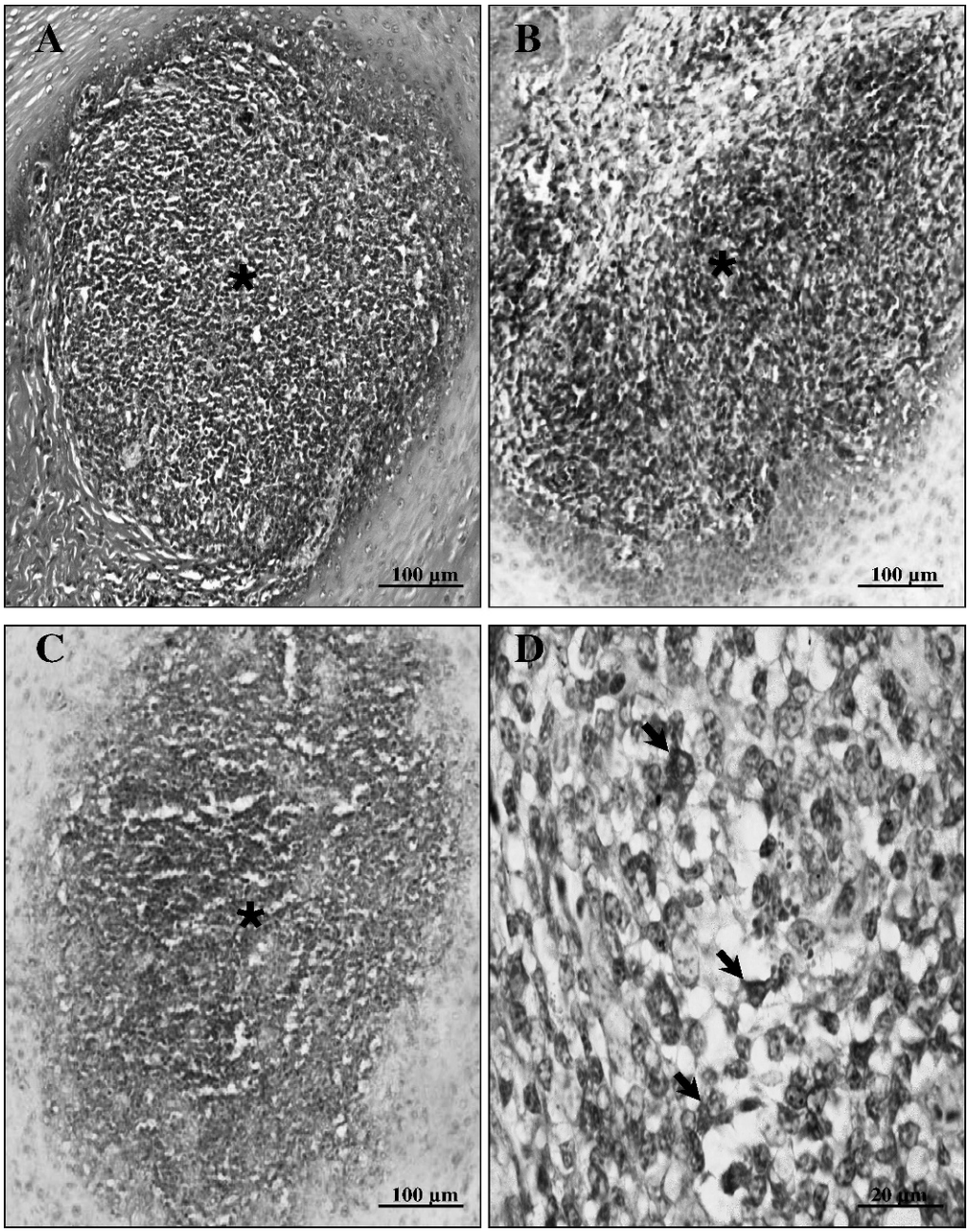

Fig. 5. General histologic and immunohistochemical (IHC) staining of isolated lymphoid follicles within the crop of specific-pathogen-free white leghorn chickens post-*Salmonella* Enteritidis (SE) challenge. Areas of positive staining are indicated by asterisks, *, or by arrows. (A) Hematoxylin and eosin staining of an isolated lymphoid follicle within the lamina propria of crop. 200× magnification. (B) IHC staining of CD45 pan-leukocyte–positive cells in the follicular structure. 200× magnification. (C) IHC staining of Bu-1–positive cells indicative of B lymphocytes within the follicle. 200× magnification. (D) Methyl green-pyronin staining for pyroninophilic cells indicative of plasma cells within an isolated lymphoid follicle of crop. 1000× magnification.

encounter a variety of exogenous environmental antigens, mitogens, or a combination from time of hatch to maturation.

The experimental oral SE infection of SPF WL chickens induced a humoral immune response that was detectable within the crop (Figs. 1–3), and SE prevalence seemed to perhaps dictate the vigorousness of the SE-LPS–specific IgA response within the crop. IgA antibody responses specific against SE-LPS antigen were observed at 1 wk after SE infection (postinfection [pi]), with a more dramatic increase in humoral response noted by 2–3 wk pi. Increased SE-LPS–specific IgA responses in crop lavage samples correlated with time points when SE was detected by bacteriologic culture from cecum samples, liver-spleen organs, or both (Figs. 1–3). Higher SE-LPS IgA values along with SE culture-positive samples were detected at time points nearer to initial oral SE infection, and then a gradual decline over time of the crop SE-LPS IgA response occurred as the percentage of SE culture-positive samples declined.

The local humoral SE-LPS–specific IgA response within the crop may not be capable of providing complete protection against a primary SE infection of naïve birds, because SE invasion of the alimentary tract and subsequent hematogenous dissemination to internal organs (liver and spleen) probably occurs before an adequate crop immune response has the chance to arise. SE positive liver-

spleen samples were detected at 1 wk pi (Figs. 1 and 3), and a heightened IgA response in the crop occurred at 2–3 wk pi (Figs. 1–3). Despite moderate to heightened SE-specific IgA responses in the crop, SE survived and persisted within the cecum at 9 wk pi, 8 wk pi, and 5 wk pi for trials 1, 2, and 3, respectively (Figs. 1–3). The immune response of the crop organ might not yield full protection against the enteroinvasive SE pathogen; however, the crop may have merit as an easy sampling site to measure mucosal humoral response of the upper gastrointestinal tract and thus help to determine chickens with active SE infection (13,28).

The chicken crop seems to be another site along the alimentary tract where inducible lymphoid tissue may be found that contributes to the integrated gut mucosal immune system. Cellular components, such as B lymphocytes and plasma cells, have the capacity to generate an IgA humoral immune response at mucosal surfaces of the alimentary tract (3,15,16). The increased presence of ILFs composed of B lymphocytes and plasma cells, and the increased SE-LPS–specific IgA within the crop samples from SE-infected chickens seems to demonstrate that a local mucosal immune response can be elicited in the crop. However, much remains to be learned about cellular and molecular events underlying the formation and function of GALT ILFs. A more detailed understanding of how SE influences the avian host immune response along the upper gastrointestinal tract (i.e., crop and proventriculus) could be important in determining how and where protective immunity against SE might be generated in poultry. Lymphoid tissue within the crop and proventriculus will be investigated further, as these two organs are in such close proximity that their cellular components (i.e., macrophages, T lymphocytes, and B lymphocytes) may interact and work in conjunction to elicit the immune response that has been detected along the upper gastrointestinal tract after oral SE challenge.

REFERENCES

1. Befus, A. D., N. Johnston, G. A. Leslie, and J. Bienenstock. Gut-associated lymphoid tissue in the chicken. I. Morphology, ontogeny, and some functional characteristics of Peyer's patches. J. Immunol. 125:2626–2632. 1980.

2. Bienenstock, J., and D. Befus. Gut- and bronchus-associated lymphoid tissue. Am. J. Anat. 170:437–445. 1984.

3. Brandtzaeg, P. Development and basic mechanisms of human gut immunity. Nutr. Rev. 56:S5–S18. 1998.

4. Brown, C. Antigen retrieval methods for immunohistochemistry. Toxicol. Pathol. 26:830–831. 1998.

5. Drayton, D. L., S. Liao, R. H. Mounzer, and N. H. Ruddle. Lymphoid organ development: from ontogeny to neogenesis. Nat. Immunol. 7:344–353. 2006.

6. Gast, R. K., and P. S. Holt. Persistence of *Salmonella* Enteritidis from one day of age until maturity in experimentally infected layer chickens. Poult. Sci. 77:1759–1762. 1998.

7. Glick, B., and I. Olah. Gut-associated-lymphoid tissue of the chicken. Scan. Electron Microsc. 99–108. 1981.

8. Hamada, H., T. Hiroi, Y. Nishiyama, H. Takahashi, Y. Masunaga, S. Hachimura, S. Kaminogawa, H. Takahashi-Iwanaga, T. Iwanaga, H. Kiyono, H. Yamamoto, and H. Ishikawa. Identification of multiple isolated lymphoid follicles on the antimesenteric wall of the mouse small intestine. J. Immunol. 168:57–64. 2002.

9. Hitotsumatsu, O., H. Hamada, M. Naganuma, N. Inoue, H. Ishii, T. Hibi, and H. Ishikawa. Identification and characterization of novel gut-associated lymphoid tissues in rat small intestine. J. Gastroenterol. 40:956–963. 2005.

10. Holt, P. S., L. E. Vaughn, R. W. Moore, and R. K. Gast. Comparison of *Salmonella* enterica serovar Enteritidis levels in crops of fed or fasted infected hens. Avian Dis. 50:425–429. 2006.

11. Holt, P. S., and R. E. Porter Jr. Effect of induced molting on the recurrence of a previous *Salmonella* Enteritidis infection. Poult. Sci. 72:2069–2078. 1993.

12. Holt, P. S., H. D. Stone, R. W. Moore, and R. K. Gast. Development of a lavage procedure to collect lung secretions from chickens for evaluating respiratory humoral immunity. Avian Pathol. 34:396–398. 2005.

13. Holt, P. S., L. E. Vaughn, R. K. Gast, and H. D. Stone. Development of a lavage procedure to collect crop secretions from live chickens for studying crop immunity. Avian Pathol. 31:589–592. 2002.

14. Iczkowski, K. A., L. Cheng, B. G. Crawford, and D. G. Bostwick. Steam heat with an EDTA buffer and protease digestion optimizes immunohistochemical expression of basal cell-specific antikeratin 34betaE12 to discriminate cancer in prostatic epithelium. Mod. Pathol. 12:1–4. 1999.

15. Iijima, H., I. Takahashi, and H. Kiyono. Mucosal immune network in the gut for the control of infectious diseases. Rev. Med. Virol. 11:117–133. 2001.

16. Ivanov, I. I., G. E. Diehl, and D. R. Littman. Lymphoid tissue inducer cells in intestinal immunity. Curr. Top. Microbiol. Immunol. 308:59–82. 2006.

17. Kajiwara, E., A. Shigeta, H. Horiuchi, H. Matsuda, and S. Furusawa. Development of Peyer's patch and cecal tonsil in gut-associated lymphoid tissues in the chicken embryo. J. Vet. Med. Sci. 65:607–614. 2003.

18. Kanter, M., A. Gul, I. Meral, A. Koc, M. Ilhan, and E. Erdogan. Morphological quantitative changes in the number of lymphocytes, macrophages and plasma cells in the uterus and lymph nodes of rats exposed to the systemic administration of BCG. Tohoku J. Exp. Med. 199:219–228. 2003.

19. Kiernan, J. A. Histological and histochemical methods theory and practice, 3rd ed. Oxford University Press, New York, NY. 2003.

20. Lorenz, R. G., D. D. Chaplin, K. G. McDonald, J. S. McDonough, and R. D. Newberry. Isolated lymphoid follicle formation is inducible and dependent upon lymphotoxin-sufficient B lymphocytes, lymphotoxin beta receptor, and TNF receptor I function. J. Immunol. 170:5475–5482. 2003.

21. Lorenz, R. G., and R. D. Newberry. Isolated lymphoid follicles can function as sites for induction of mucosal immune responses. Ann. N Y Acad. Sci. 1029:44–57. 2004.

22. McDonald, K. G., J. S. McDonough, and R. D. Newberry. Adaptive immune responses are dispensable for isolated lymphoid follicle formation: antigen-naive, lymphotoxin-sufficient B lymphocytes drive the formation of mature isolated lymphoid follicles. J. Immunol. 174:5720–5728. 2005.

23. Mestecky, J., M. W. Russell, and C. O. Elson. Intestinal IgA: novel views on its function in the defense of the largest mucosal surface. Gut 44:2–5. 1999.

24. Olah, I., and B. Glick. Structure of the germinal centers in the chicken caecal tonsil: light and electron microscopic and autoradiographic studies. Poult. Sci. 58:195–210. 1979.

25. Olah, I., N. Nagy, A. Magyar, and V. Palya. Esophageal tonsil: a novel gut-associated lymphoid organ. Poult. Sci. 82:767–770. 2003.

26. Opstad, A. M. A methyl green-pyronin stain for plasma cells in tissues. Stain Technol. 34:293. 1959.

27. Seo, K. H., P. S. Holt, R. E. Brackett, R. K. Gast, and H. D. Stone. Mucosal humoral immunity to experimental Salmonella enteritidis infection in the chicken crop. Avian Dis. 46:1015–1020. 2002.

28. Seo, K. H., P. S. Holt, L. E. Vaughn, R. K. Gast, and H. D. Stone. Detection of *Salmonella* enteritidis-specific immunoglobulin A antibodies in crop samples from chickens infected with Salmonella enteritidis. Poult. Sci. 82:67–70. 2003.

29. Taylor, R. T., and I. R. Williams. Lymphoid organogenesis in the intestine. Immunol. Res. 33:167–181. 2005.

30. Vaughn, L. E., P. S. Holt, R. W. Moore, R. K. Gast, and K. E. Anderson. Crop immune response post-*Salmonella* Enteritidis challenge in eight commercial egg-layer strains and specific-pathogen-free white leghorn chickens. Avian Dis. 52:79–87. 2008.