AVIAN DISEASES 57:650–656, 2013

Effect of Coronavirus Infection on Reproductive Performance of Turkey Hens

Olusegun O. Awe,[AB] Ahmed Ali,[AB] Mohamed Elaish,[AB] Mahmoud Ibrahim,[AC] Maria Murgia,[AB] Mary Pantin-Jackwood,[D] Yehia M. Saif,[AB] and Chang-Won Lee[ABE]

[A]Food Animal Health Research Program, Ohio Agricultural Research and Development Center, Wooster, OH 44691
[B]Department of Veterinary Preventive Medicine, College of Veterinary Medicine, The Ohio State University, Wooster, OH 44691
[C]Department of Poultry Diseases, Faculty of Veterinary Medicine, Menoufia University, Menoufia, 22857 Egypt
[D]Southeast Poultry Research Laboratory, United States Department of Agriculture, Agricultural Research Service, Athens, GA 30605

Received 26 January 2013; Accepted 15 May 2013; Published ahead of print 15 May 2013

SUMMARY. Turkey coronavirus (TCoV) infection causes enteritis in turkeys of varying ages with high mortality in young birds. In older birds, field evidence indicates the possible involvement of TCoV in egg-production drops in turkey hens. However, no experimental studies have been conducted to demonstrate TCoV pathogenesis in turkey hens and its effect on reproductive performance. In the present study, we assessed the possible effect of TCoV on the reproductive performance of experimentally infected turkey hens. In two separate trials, 29- to 30-wk-old turkey hens in peak egg production were either mock-infected or inoculated orally with TCoV (Indiana strain). Cloacal swabs and intestinal and reproductive tissues were collected and standard reverse-transcription PCR was conducted to detect TCoV RNA. In the cloacal swabs, TCoV was detected consistently at 3, 5, 7, and 12 days postinoculation (DPI) with higher rates of detection after 5 DPI (>90%). All intestinal samples were also positive for TCoV at 7 DPI, and microscopic lesions consisting of severe enteritis with villous atrophy were observed in the duodenum and jejunum of TCoV-infected hens. In one of the trials TCoV was detected from the oviduct of two birds at 7 DPI; however, no or mild microscopic lesions were present. In both experimental trials an average of 28%–29% drop in egg production was observed in TCoV-infected turkey hens between 4 and 7 DPI. In a separate trial we also confirmed that TCoV can efficiently transmit from infected to contact control hens. Our results show that TCoV infection can affect the reproductive performance in turkey hens, causing a transient drop in egg production. This drop in egg production most likely occurred as consequence of the severe enteritis produced by the TCoV. However, the potential replication of TCoV in the oviduct and its effect on pathogenesis should be considered and further investigated.

RESUMEN. Efecto de la infección por coronavirus sobre el comportamiento reproductivo de las pavas.

La infección por el coronavirus de los pavos (TCoV) causa enteritis en pavos de diferentes edades, con una mortalidad alta en aves jóvenes. En aves de mayor edad, la evidencia de campo indica la posible participación de este coronavirus en caídas de la producción de huevos en pavas. Sin embargo, no se han desarrollado estudios experimentales para demostrar la patogénesis de este coronavirus en pavas y su efecto en el rendimiento reproductivo. En el presente estudio, se evaluó el posible efecto del coronavirus de los pavos en el comportamiento reproductivo de pavas infectadas experimentalmente. En dos ensayos por separado, pavas de 29 a 30 semanas de edad que se encontraban en el pico de producción de huevos, fueron inoculadas con un placebo o fueron infectadas oralmente con el coronavirus de los pavos (cepa Indiana). Se recolectaron hisopos cloacales, tejidos intestinales y reproductivos y se llevó a cabo un método estándar de transcripción reversa y PCR para detectar al ARN del coronavirus de los pavos. Se detectó a este coronavirus en hisopos cloacales consistentemente a los tres, cinco, siete, y doce días después de la inoculación con tasas mayores de detección después de los cinco días después de la inoculación (> 90%). De la misma forma, todas las muestras intestinales fueron positivas para la presencia del coronavirus de los pavos a los siete días después de la inoculación y se observaron lesiones microscópicas que consistían en enteritis severa con atrofia de las vellosidades en el duodeno y en el yeyuno de gallinas infectadas con este coronavirus. En uno de los ensayos, se detectó al coronavirus de los pavos en el oviducto de dos aves a los siete días después de la inoculación, sin embargo, no se detectaron lesiones microscópicas leves. En ambos ensayos experimentales se observó en promedio una caída en la producción de huevo del 28% al 29% en las pavas infectadas con el coronavirus entre cuatro a siete días. En otro experimento separado, también confirmó que este virus de los pavos se puede transmitir de manera eficiente por contacto entre las aves infectadas y las pavas controles. Estos resultados muestran que la infección por el coronavirus de los pavos puede afectar la capacidad reproductora en pavas, causando una caída transitoria en la producción de huevos. Es muy probable que esta caída en la producción de huevos se haya producido como consecuencia de la enteritis grave producida por este virus. Sin embargo, se debe considerar e investigar más a fondo la replicación potencial de este virus en el oviducto y su efecto sobre la patogénesis.

Key words: turkey, coronavirus, enteritis, egg production

Abbreviations: DPC = days postcontact (contact group); DPI = days postinoculation (inoculated group); EID_{50} = 50% egg infectious dose; IBV = infectious bronchitis virus; PBS = phosphate-buffered saline; PEC = poult enteritis complex; PEMS = poult enteritis mortality syndrome; RT-PCR = reverse transcription-PCR; TCoV = turkey coronavirus

Coronaviruses are large, enveloped, nonsegmented, positive-sense single-stranded RNA viruses belonging to the family *Coronaviridae* (6). Their genome is approximately 30 kb long from which they transcribe a set of multiple 3′-coterminal nested subgenomic mRNA (20). The virus possesses roughly spherical, pleomorphic virions with diameters ranging from 50–200 nm with characteristic, petal-shaped spikes on their surface that are responsible for their crown-shaped morphologic appearance, as observed using an electron microscope (10). The virus particle consists of four major structural proteins including the highly variable spike (S) glycoprotein, the conserved membrane (M), the nucleocapsid (N), and the small envelop (E) proteins. The most economically significant coronaviruses affecting

[E]Corresponding author. 1680 Madison Avenue, Wooster, OH 44691. E-mail: lee.2854@osu.edu

the poultry industry belong to the genus *Gammacoronavirus*, which mainly consists of coronaviruses isolated from birds, including turkey coronavirus (TCoV) and infectious bronchitis virus (IBV) of chicken (11).

In the 1970s TCoV was shown to be an important cause of enteric disease of turkeys, was termed transmissible gastroenteritis, coronaviral enteritis, or blue comb disease, and resulted in severe economic losses to the poultry industry (18). The infectious diarrhea caused by TCoV in turkey poults had a negative impact on growth rate and feed conversion efficiency, with varying mortality associated with a significant economic loss (13). TCoV has also been implicated in severe infectious disease of young turkey poults up to 7 wk of age, termed poult enteritis complex (PEC). The clinical signs of PEC include diarrhea, dehydration, stunted growth, inappetence, weight loss, uneven flock growth, and dysfunctions of the immune system. When PEC is coupled with the clinical manifestation of mortality in young birds, it is also called poult enteritis mortality syndrome (PEMS) (2).

TCoV is antigenically and genetically related to IBV, based on studies showing cross-reactivity between the two viruses in immunofluorescence and enzyme-linked immunosorbent assays (14). In addition, studies showed that the order of the genes at the 3′ ends of the genome of both TCoV and IBV were similar, except for the spike glycoprotein gene (5), suggesting that TCoV might have emerged from IBV (12). IBV affects chickens of all ages, causing highly contagious respiratory disease (17). IBV targets not only the respiratory tract but also the urogenital tract, with infection of the oviduct possibly leading to permanent damage in immature birds and a decline in egg production in laying hens (3). The production change is also coupled with a decline in the quality of eggs, with an increase in the number of eggs unacceptable for setting, a reduced hatchability, and production of soft-shelled, rough-shelled, and misshapen eggs with a loss of shell pigmentation (3).

Like IBV, turkey coronavirus has also been linked with a rapid drop in egg production and quality in turkey breeder hens (8,18). It has been speculated that TCoV infection of breeder turkeys usually leads to deterioration in eggshell quality, with chalky shells lacking pigmentation, and that the only clinical sign that may appear in breeder turkeys may be a sudden drop in egg production (8). Although circumstantial evidence indicates the involvement of TCoV in drops in egg production in laying hens, no experimental studies have been conducted to demonstrate the pathogenesis of TCoV in laying hens. In this study, the potential effect of TCoV on egg production in layer turkey hens was assessed experimentally for the first time.

MATERIALS AND METHODS

Virus preparation. TCoV (Indiana strain) was isolated from the intestines of turkey poults in Indiana experiencing an outbreak of acute enteritis. The intestines were homogenized with a 5-fold volume of sterile phosphate-buffered saline (PBS pH 7.2) followed by centrifugation at 2000 × *g* for 10 min at 4 C and filtration through 0.45- and 0.22-μm membrane filters (Millipore Products Division, Bedford, MA). TCoV NRC-47 was propagated once by inoculation in 22-day-old embryonated turkey eggs via the amniotic route to make a virus stock (21). Virus titer was determined using embryonated turkey eggs by inoculating 10-fold serial dilutions of virus. Embryos positive for coronaviral RNA by reverse transcription-PCR (RT-PCR) were recorded and titer was determined using the Reed and Muench method (22).

Experimental infection study to determine the pathogenesis of TCoV in turkey hens. Two trials were conducted using 26-wk-old turkey hens. Turkey hens for trial 1 were obtained from the Ohio Agricultural Research Development Center (OARDC) flock, Wooster, Ohio, while birds for the second trial were from a commercial farm in Ohio. The hens were housed in isolation rooms in cages specifically made for laying turkey hens with *ad libitum* access to feed and water.

Trial 1. Twenty-four laying hens were observed until about 90% egg production was attained (approximately the 30th wk of age). Birds were separated into 2 groups ($n = 12$ per group). The first group of birds was inoculated orally with 2 ml of the TCoV ($\sim 10^5$ 50% egg infectious dose [EID_{50}]/ml) each and the second group with TCoV-negative intestinal homogenate derived from PBS-inoculated turkey embryos. Egg production was monitored twice daily. At 7 and 14 days postinoculation (DPI), cloacal swabs were collected from all birds. Four birds at 7 DPI and the remaining eight birds at 14 DPI were euthanatized and examined for gross pathology, and tissues were collected from the intestines (jejunum and ileum) and the reproductive tracts (infundibulum, magnum, isthmus, and uterus) into PBS for virus detection. Tissues were also collected for histopathologic examination. For this, tissues were fixed by submersion in 10% neutral buffered formalin, routinely processed, and embedded in paraffin. Sections were made at 5 μm and were stained with hematoxylin and eosin (H&E). Intestinal contents were also collected from the jejunum and ileum for virus detection.

Trial 2. Forty-eight turkey hens were separated into four groups ($n = 12$ birds per group). At approximately the 29th week of age, groups I and II were inoculated orally with 1 ml of the TCoV preparation ($\sim 10^7$ EID_{50}/ml). Group III and IV received TCoV-negative intestinal homogenate from PBS-inoculated turkey embryos. Egg production was monitored from hens in group I and III twice daily while birds in groups II and IV were utilized for sample collection. Cloacal swabs were collected from all birds in groups II and IV at 3, 5, and 7 DPI. In addition, four birds from groups II and IV were euthanatized at 7 DPI and intestinal (jejunum and ileum) and reproductive tissues (infundibulum, magnum, isthmus, and uterus) were collected. At the end of the experiment (12 DPI), cloacal swabs and intestinal and reproductive tissues were collected from the remaining birds in groups I and III, as in trial 1.

Experimental infection study to determine the transmission efficiency of TCoV. Twelve turkey hens from the OARDC flock were used to study the direct transmission of TCoV from infected to contact control birds. At approximately the 29th week of age, six birds were each orally inoculated with 1 ml of TCoV and housed on the floor of an isolation room with litter. One day after infection, six uninoculated turkey hens (contact control birds) were moved into the same room with the infected birds. Cloacal swabs were collected daily from both infected and contact control birds for 18 days. At 10 and 18 DPI, two and four birds, respectively, from infected and contact control birds were euthanatized to collect intestinal tissues (jejunum and illeum) for virus detection, as described below.

Sample preparation, RNA extraction, and RT-PCR. Swab and tissue samples from all experiments were processed as previously described (7). Briefly, swab samples were vortexed and then centrifuged at 2000 × *g* for 2 min at 4 C to pellet the debris. Tissues were homogenized in sterile PBS (1:5 ratios w/v) and then centrifuged at 2000 × *g* for 10 min at 4 C to pellet the tissue debris. RNA was extracted from 200 μl of the swab samples and tissue homogenate supernatants using an RNeasy Mini kit (Qiagen, Inc., Valencia, CA) according to the manufacturer's instruction. All samples collected were subjected to virus detection by standard RT-PCR using a TCoV 3′ untranslated region (UTR)-specific primer set as previously described (9).

RESULTS

Pathogenesis of TCoV in turkey hens. *Trial 1*. We observed a drop in egg production 1 day after inoculation, which was possibly due to handling stress, in both mock-infected and TCoV infected groups, but they returned to normal levels of production by 3 DPI. However, a decline in egg production was observed in the infected

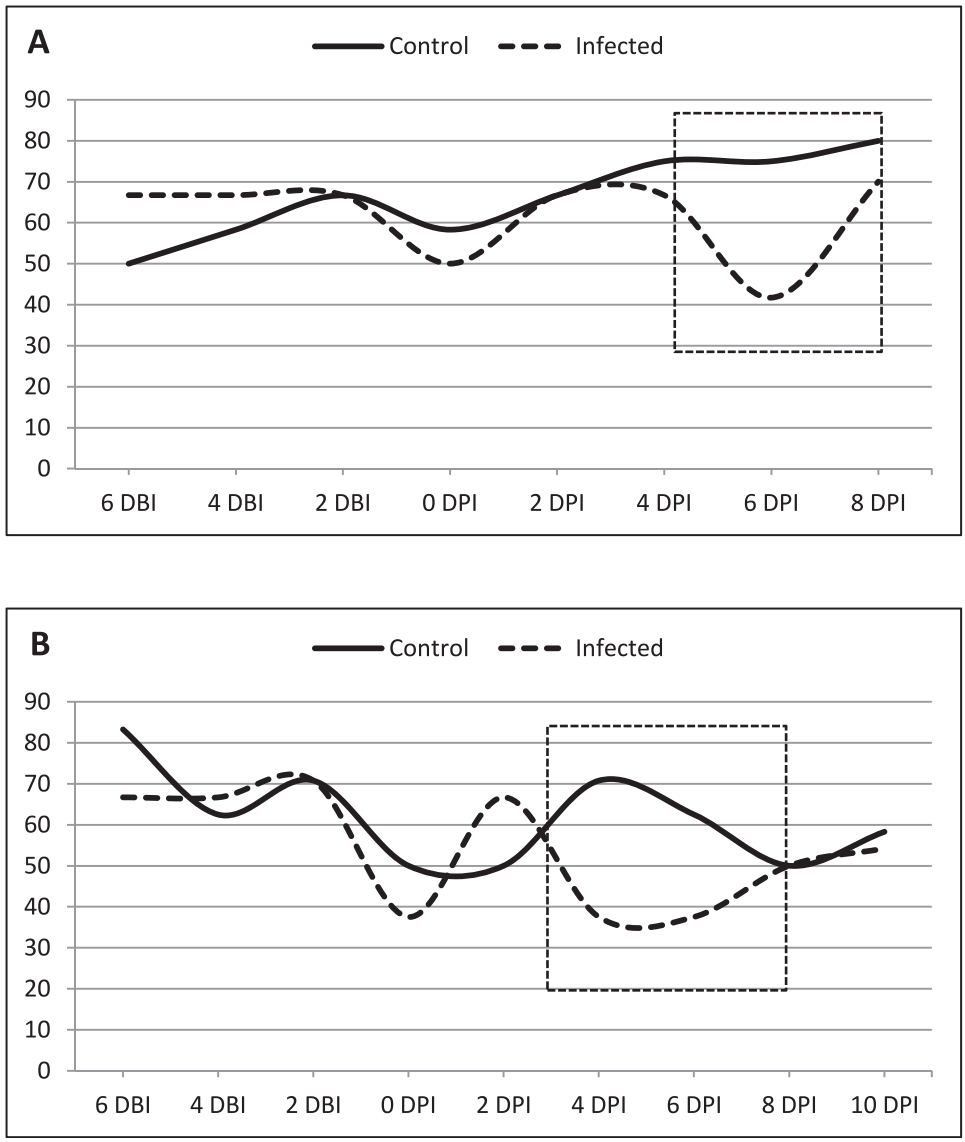

Fig. 1. Egg production data from infected and uninfected control layer turkey hens in first (A) and second (B) experiments. The *x*-axis represents days in egg production, 2 days being represented as one unit. The *y*-axis represents the percent egg production. Dotted box indicates transient egg-production drop between 4–7 dpi. DBI = days before inoculation; DPI = days postinoculation.

bird group between 5 and 7 DPI. During this time, average egg production in infected hens declined by 27.7% as compared with the control group. The egg production in the TCoV-infected group returned to a normal level, similar to the control group, around 8 DPI (Fig. 1A). Apart from the lowered egg production, no other clinical signs were observed in both experimental groups and egg quality appeared to be normal.

Necropsy of infected birds at 7 and 14 DPI revealed severe intestinal pathology. Intestinal tracts of all birds were inflamed, discolored, and distended with yellowish, frothy exudates (Fig. 2). Microscopically, lesions were similar to those reported in TCoV infections of turkey poults (13,14). Severe enteritis with villous atrophy, with expansion of the lamina propria by inflammatory cells, was observed in the duodenum and more consistently in the jejunum

→

Fig. 2. Pathologic changes produced by coronavirus in experimentally inoculated layer turkey hens. (A) Ruptured ova at 14 DPI; (B) congested and thickened intestine at 14 DPI (arrow head); (C) severely congested jejunum (*j*) and ileum (*i*) mucosa at 3 DPI; (D) gaseous and distended cecum (arrow head).

Fig. 3. Histopathologic lesions in laying turkey hens infected with TCoV. (A) Jejunum from TCoV-infected turkey hen, 7 DPI. Severe enteritis. Sloughing of the epithelium on the tips of the villi (arrow) resulting in blunting and fusion of the villi. Congestion and infiltration of the lamina propria with lymphocytes and some heterophils, 200×. (B) Duodenum from TCoV-infected hen, 14 DPI. Severe lymphocytic enteritis, 200×. (C) Uterus (shell gland) from mock-infected control hens, 7 DPI, 400×. (D) Uterus from TCoV-infected hen, 7 DPI. Desquamation of the surface epithelium (arrows) and glandular depletion, 400×.

2

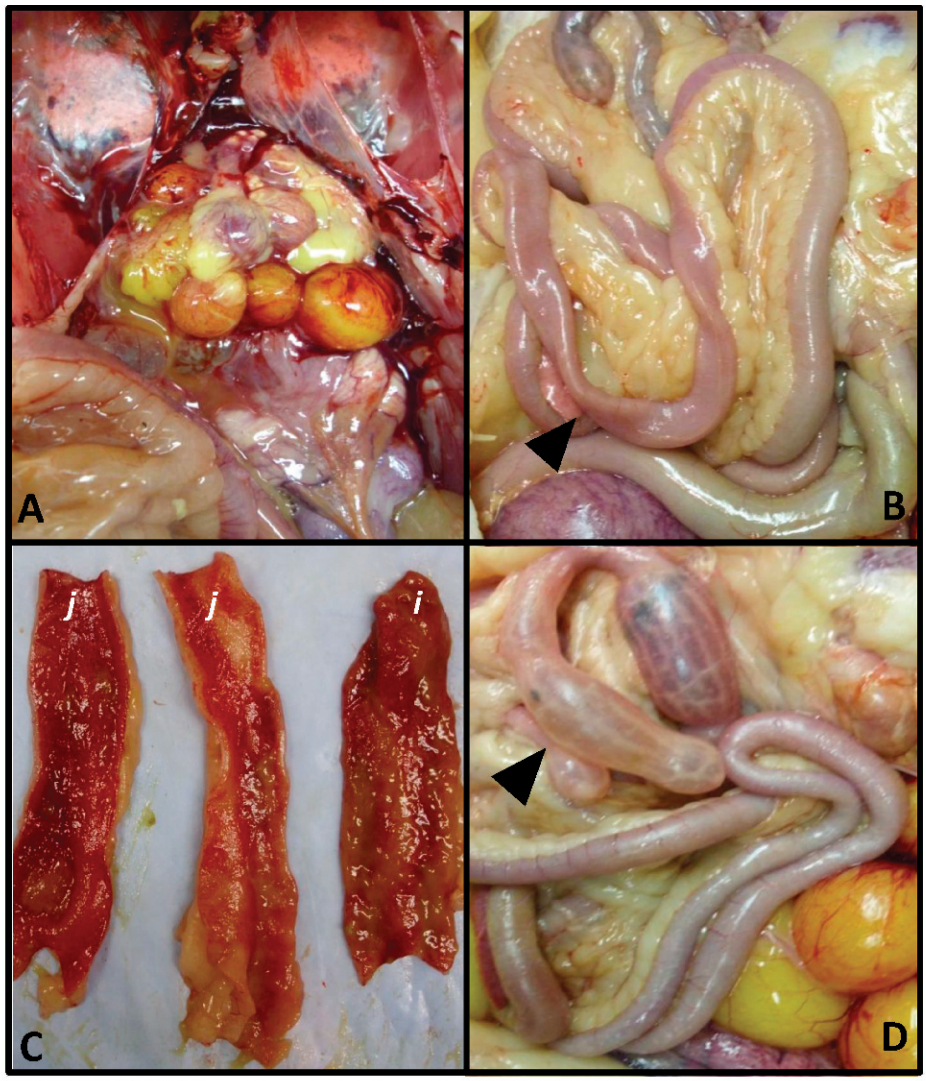

3

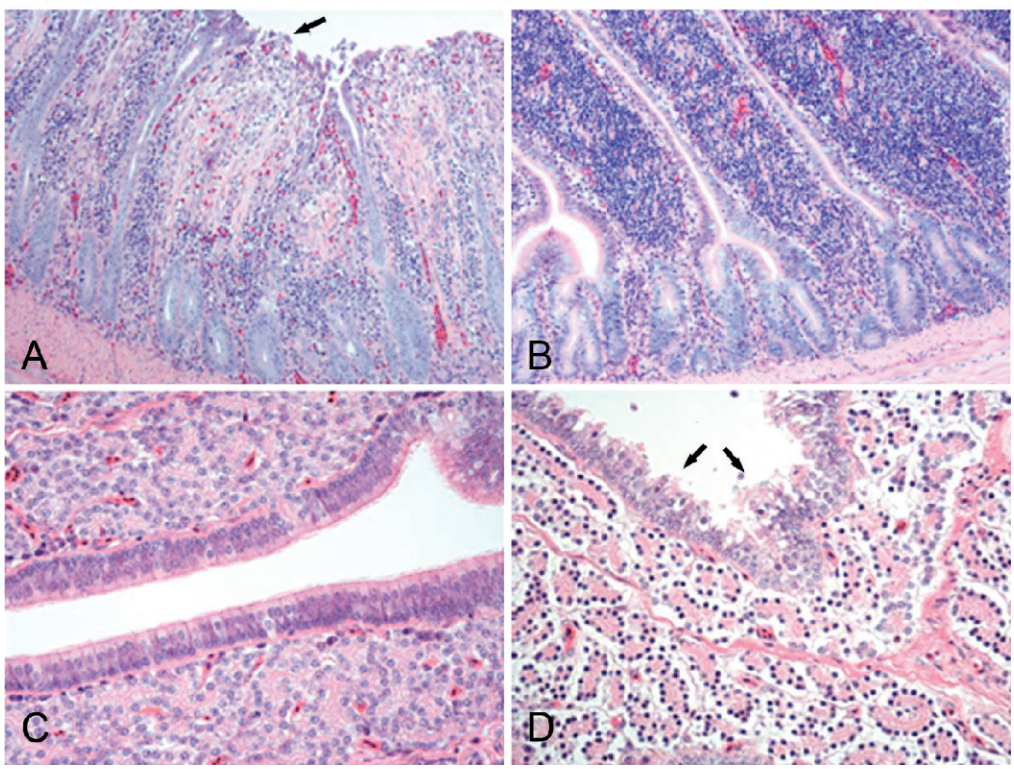

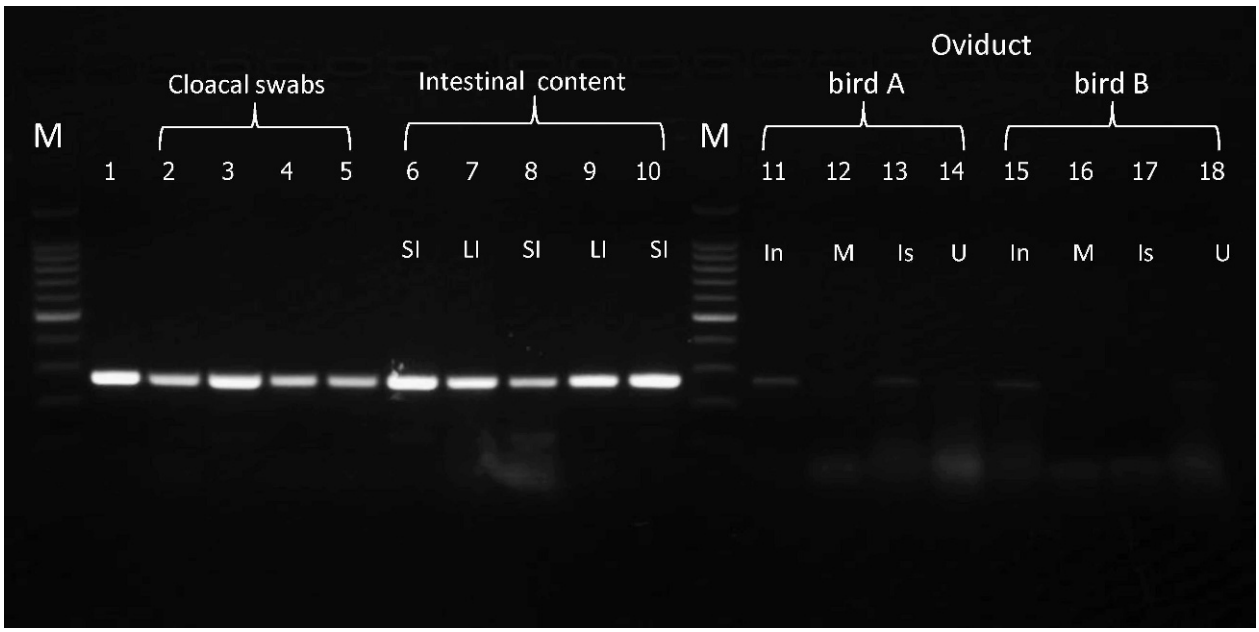

Fig. 4. TCoV detection by RT-PCR in the cloacal swabs, intestinal contents, and reproductive tissues of infected layer turkey hens at 7 DPI. Lane M = 100-bp DNA marker; Lane 1 = TCoV-positive control RNA; Lanes 2–5 = cloacal swabs; Lanes 6–10 = intestinal contents of infected hens (SI = small intestine, LI = large intestine); Lanes 11–18 = oviduct compartments (In = infundibulum, M = magnum, Is = isthmus, and U = uterus). Although not shown clearly in the picture, all samples from bird A and the infundibulum and uterus from bird B were PCR-positive.

at both time points (Fig. 3A,B). Sloughing of epithelial cells, congestion, and in some cases hemorrhage, and widespread infiltration of lymphocytes and heterophils into the lamina propria of the villi was observed especially at 7 DPI. Also common was the fusion of adjacent shortened villi. At 12 DPI the inflammatory infiltration of the lamina propria was still pronounced, and numerous enterocytes undergoing division were observed in the crypts. The reproductive tracts also presented with lesions on postmortem examination. Although retention of ovarian follicles was observed in two control birds, the pathologic lesions observed in ovaries of TCoV-infected turkey hens were much more marked and included retained, pedunculated, ruptured, and malformed ovarian follicles. At 7 DPI, two virus-inoculated birds had atrophied oviducts with the presence of ruptured yolk in the abdomen that led to egg peritonitis (Fig. 2A). Microscopically, in the oviduct there was a decrease in the number and size of secretory glands in the lamina propria, reflecting their inactivity, but with no signs of inflammation (salpingitis). However, in some hens loss of the surface epithelium in different sections of the oviduct was also observed (Fig. 3D). At 14 DPI no microscopic lesions were present in the oviduct of virus-infected hens. TCoV was detected in cloacal swabs of all infected birds at 7 DPI by RT-PCR but no virus was detected at 14 DPI (Fig. 4). Small and large intestinal contents of all infected hens were also positive for TCoV at 7 DPI; however, at 14 DPI we were able to detect the virus from only one large-intestinal sample. The virus was also detected in all parts of the reproductive tract of one bird and the infundibulum and uterus of another hen. We confirmed the TCoV gene by partial sequencing of the 250-bp RT-PCR product.

Trial 2. In the second experiment, we separated the groups for monitoring of egg production and sampling to minimize the possible effect of bird handling on the egg production. Similar to the first trial, decline in egg production (average of 29.2%) between 4 and 7 DPI was observed in infected hens, with egg production returning to a normal level at 8 DPI (Fig. 1B). Consistent with our first trial, no effect on egg quality was observed following experimental infection of TCoV. Also, the intestinal pathology observed was similar to that observed in trial 1. The lesions included paleness and congestion of the jejunum and ileum (Fig. 2B,C) and distention with gaseous, frothy contents in the cecum (Fig. 2D). Microscopic lesions were similar to those observed in trial 1. In contrast to our first trial, the only pathologic gross lesion observed in the reproductive tracts of one TCoV-inoculated bird was congestion and a prolapsed uterus. No significant microscopic lesions were observed in the oviduct of the TCoV-infected hens. TCoV was detected consistently in fecal swabs from infected birds at 3, 5, 7, and 12 DPI. Half of the cloacal swabs sampled from infected hens at 3 DPI were TCoV positive while about 90% of the samples were positive at 5 DPI. TCoV was detected in all cloacal swabs from infected birds collected both at 7 and 12 DPI. The virus was not detected in any part of the reproductive tissues.

Transmission of TCoV to contact control birds. TCoV shedding in fecal swabs of both infected and contact control layer turkey hens is shown in Table 1. TCoV was detected as early as 3 DPI from infected birds, and 50% of the birds at 5 DPI were positive. The virus shedding increased to about 80% at 6 DPI and all inoculated hens were shedding TCoV at 7 and 9 DPI. Although the detection rate decreased after 9 DPI, the viral RNA was detected until the end of the experiment (18 DPI). In contact control hens all swabs were positive for TCoV as early as 3 days postcontact (DPC) and about an 80% detection rate was maintained up to 12 DPI. As in inoculated birds, we were able to detect viral RNA until 18 DPI. Consistent with cloacal swab results, all small- and large-intestinal contents collected from inoculated and contact control hens at 10 DPI (or 9 DPC) were positive for TCoV. Also, 50%–100% of the intestinal tissue samples (jejunum and ileum) from the inoculated group and contact group, collected at 11 and 18 DPI and at 10 and 17 DPC, respectively, were TCoV positive. Similar gross pathology (e.g., distended intestine with gaseous, frothy contents) was observed at 10 and 18 DPI in both infected and contact control hens, as observed in other two trials described above.

Table 1. Virus detection by RT-PCR in cloacal swabs, jejunum, and ileum of TCoV-infected and contact control turkey hens.

		DPI (inoculated group) and DPC (contact group)																	
Group	Sample	1	2	3	4	5	6	7	8	9	10	11	12	13	14	15	16	17	18
Inoculated	Cloacal swab	1/6[A]	1/6	2/6	2/6	3/6	5/6	6/6	5/6	6/6	4/6	2/4	2/4	1/4	1/4	1/4	1/4	1/4	1/4
	Jejunum	—[B]	—	—	—	—	—	—	—	—	—	1/2	—	—	—	—	—	—	3/4
	Ileum	—	—	—	—	—	—	—	—	—	—	2/2	—	—	—	—	—	—	2/4
Contact	Cloacal swab	—	0/6	0/6	6/6	6/6	6/6	2/6	5/6	5/6	5/6	3/4	3/4	1/4	0/4	0/4	0/4	2/4	1/4
	Jejunum	—	—	—	—	—	—	—	—	—	—	1/2	—	—	—	—	—	—	2/4
	Ileum	—	—	—	—	—	—	—	—	—	—	2/2	—	—	—	—	—	—	3/4

[A]No. of hens positive with RT-PCR/total no. of hens.
[B](—) = not tested.

DISCUSSION

TCoV is an important viral enteric pathogen of turkeys causing infectious diarrhea (10). The disease termed coronaviral enteritis or transmissible gastroenteritis is characterized by decreased weight gain, impaired feed utilization, increased mortality, and uneven flock growth in turkeys and has been incriminated as one of the important causative agents of PEMS (24). Turkeys of all ages are affected, resulting in increased morbidity and mortality and significant economic loss to the poultry industry (13,16). Although TCoV is reported to have a strict tropism for turkey intestinal epithelium and bursa of Fabricius (14), field reports implicated TCoV as a potential cause of egg production problems in layer turkeys (8). In addition, using electron microscopy we detected coronavirus in the oviduct of turkey hens that experienced a drop in egg production (Y. M. Saif, unpubl. data). In this study a transient decline in egg production between 4 and 7 DPI was observed in TCoV-infected hens. The average egg production drop was similar in both trials (28%–29%); also, the similar peak egg production drop (approximately 35%) was observed in the first (at 6 DPI) and second (at 5 DPI) trials. Although we detected TCoV in the oviduct tissues of two infected birds at 7 DPI in trial 1, and mild damage to the oviduct epithelium and glandular depletion was observed, we considered that the transient drop in the egg production might not be due to direct replication of TCoV in the reproductive tracts, as the virus detection was not a consistent finding in all samples collected at different time points or in both experimental trials conducted. On the other hand, not every hen had a drop in egg production, which might indicate that the decreased egg production occurred only in hens that had severe intestinal infection and pathologic changes. No effect on egg quality was observed in our study as opposed to a previous report of field-outbreak observations (8). It is possible that other factors in the field (e.g., environmental, management, or concurrent presence of other pathogens, etc.) may have contributed to disease severity and malformation or to the poor quality of eggs. Gross lesions were observed in the ovary of virus-infected hens and could explain the drop in egg production; however, microscopic lesions and presence of the virus in the ovaries were not assessed in this study. Future studies examining for the presence of TCoV in reproductive tissues by viral antigen staining (immunohistochemistry) will help elucidate the role of TCoV in the pathogenesis observed.

The shedding pattern of TCoV in cloacal contents of infected turkey hens was determined by RT-PCR. In our first trial, TCoV could be detected in cloacal swabs at 7 DPI from all inoculated birds but not at 14 DPI. TCoV RNA detection in fecal swabs of infected birds correlated with virus detection in small- and large-intestinal contents at 7 DPI, in which we found all samples positive, whereas only one weak positive sample was observed at 14 DPI. In the second trial, TCoV was consistently detected in fecal swabs throughout the 12 days of the experimental period. At 3, 5, and 7 DPI, 50, 90, and 100%, respectively, of inoculated birds shed the virus. Although TCoV was not detected in fecal swabs at 14 DPI in the first trial, the duration of TCoV shedding in infected layers in our study is almost similar to the shedding pattern observed in poults, in which TCoV shedding was detected up to 2 wk after inoculation using the TCoV ATCC R 911 strain (16).

TCoV replicates in the intestines, and the virus is shed in feces of infected birds. Virus shedding in feces may thus be an important avenue for the transmission of TCoV to other birds on the farm, especially for birds housed on the floor with litter. We evaluated the potential of TCoV transmission from infected layer turkey hens to contact hens. The early detection of TCoV shedding in all contact birds at 3 DPC shows that TCoV transmits rapidly and efficiently from infected to contact hens via a fecal-oral route. Our findings also suggest that contact hens can shed TCoV for a similar duration as infected hens through reinfection (Table 1). Although our study ended at 18 DPI, based on viral detection from most of the intestinal tissues tested at 18 DPI (Table 1) we expect sporadic detection of TCoV from both infected and contact control hens for a longer period of time.

As an enteric pathogen, TCoV damages intestinal epithelium and leads to impaired food absorption, diarrhea, and enteritis (13). In the present study we observed a progression of intestinal pathology in layer turkey hens challenged with TCoV. Acute lesions due to the replication of TCoV in the intestines of challenged birds were observed at 3 DPI; intestines of inoculated hens appeared thickened and the jejunum and ileum were congested with hemorrhages. These intestinal lesions are consistent with TCoV replication in poults, which has been reported to be primarily in the enterocytes of the jejunum and ileum (4,15). We also observed gross pathology in the large intestines. The cecum and colon were markedly distended with gaseous, frothy contents. Intestinal distension with gas was more pronounced in birds at 5 DPI; however, by 7 DPI intestinal lesions in infected hens progressed to paleness and thickening of the duodenum and jejunum, coupled with a markedly distended large intestine. Thickening of the intestines was observed in all 12 infected birds at 12 DPI. Gross pathology observed in our study was similar to that previously encountered in poults, where the intestines of infected poults showed marked enlargement with loose contents (16). The lesions were demonstrated to be associated with depression, anorexia, decreased water consumption, watery diarrhea, and poor growth performance (16,24).

Gross pathologic examination of the reproductive organs also revealed lesions in the ovary and some parts of the oviduct, especially in the first trial. At 7 DPI, minimal lesions of retained ova among normal-appearing ovules were observed in control birds; however, ovarian lesions were much more pronounced in infected hens with misshapen, mal-developed ovaries and an accumulation of caseous

exudates in the peritoneum. The fluid yolk material found in the abdominal cavity of infected birds at 14 DPI may be associated with the rupture of mal-developed ovaries leading to peritoneal adhesions of the oviduct. IBV, a close relative of TCoV, has been reported to cause reproductive tract lesions in chickens, although severe lesions are observed less in older birds (1).

The decreased egg production in our study is similar to that observed with another enteric pathogen where layer chickens experimentally inoculated with rotavirus showed a drop in egg production from 4–9 DPI (23). The egg production decline was attributed to the stress of rotavirus infection. This may also explain the pattern of transient egg production drop observed in our study, as egg production decline coincided with severe intestinal pathology and high incidence of virus shedding in fecal swabs. A similar transient decrease in egg production, with little or no pathology and virus in the oviduct, was also reported in laying chicken hens infected with a low pathogenic avian influenza virus and, in that case, it was proposed that the virus infection caused distress or affected feed and water consumption enough to affect lay (19). However, the potential replication of TCoV in the oviduct and its pathogenesis for reproductive tissues should be further investigated. To our knowledge, our experimental study is the first to demonstrate the effect of TCoV infection on reproductive performance of layer turkeys.

REFERENCES

1. Alexander, D. J., and R. E. Gough. Isolation of avian infectious bronchitis virus from experimentally infected chickens. Res. Vet. Sci. 23:344–347. 1977.

2. Barnes, H. J., J. S. Guy, and J. P. Vaillancourt. Poult enteritis complex. Rev. Sci. Tech. 19:565–588. 2000.

3. Bisgaard, M. [The influence of infectious bronchitis virus on egg production, fertility, hatchability and mortality rate in chickens (author's transl.)]. Nord. Vet. Med. 28:368–376. 1976.

4. Breslin, J. J., L. G. Smith, H. J. Barnes, and J. S. Guy. Comparison of virus isolation, immunohistochemistry, and reverse transcriptase-polymerase chain reaction procedures for detection of turkey coronavirus. Avian Dis. 44:624–631. 2000.

5. Breslin, J. J., L. G. Smith, F. J. Fuller, and J. S. Guy. Sequence analysis of the turkey coronavirus nucleocapsid protein gene and 3′ untranslated region identifies the virus as a close relative of infectious bronchitis virus. Virus Res. 65:187–193. 1999.

6. Cavanagh, D., K. Mawditt, M. Sharma, S. E. Drury, H. L. Ainsworth, P. Britton, and R. E. Gough. Detection of a coronavirus from turkey poults in Europe genetically related to infectious bronchitis virus of chickens. Avian Pathol. 30:355–368. 2001.

7. Chen, Y. N., C. C. Wu, T. Bryan, T. Hooper, D. Schrader, and T. L. Lin. Specific real-time reverse transcription-polymerase chain reaction for detection and quantitation of turkey coronavirus RNA in tissues and feces from turkeys infected with turkey coronavirus. J. Virol. Methods 163:452–458. 2010.

8. Clark, F. D. Coronavirus infections in turkeys. In: Avian Advice Newsletter (Extension Poultry Veterinarian Center of Excellence for Poultry Science, University of Arkansas Cooperative Extension Service). 2008.

9. Culver, F. A., P. Britton, and D. Cavanagh. RT-PCR detection of avian coronaviruses of galliform birds (chicken, turkey, pheasant) and in a parrot. Methods Mol. Biol. 454:35–42. 2008.

10. Dea, S., G. Marsolais, J. Beaubien, and R. Ruppanner. Coronaviruses associated with outbreaks of transmissible enteritis of turkeys in Quebec: hemagglutination properties and cell cultivation. Avian Dis. 30:319–326. 1986.

11. de Groot, R. J., J. Ziebuhr, L. L. Poon, P. C. Woo, P. Talbot, P. J. M. Rottier, K. V. Holmes, R. Baric, S. Perlman, L. Enjuanes, and A. E. Gorbalenya. Taxonomical proposal to the ICTV Executive Committee: revision of the family Coronaviridae. [cited 22 June 2012]. Available at: http://talk.ictvonline.org/files/ictv_official_taxonomy_updates_since_the%20_8th_report/m/vertebrate-2008/1230/download.aspx. 2008.

12. Gomaa, M. H., J. R. Barta, D. Ojkic, and D. Yoo. Complete genomic sequence of turkey coronavirus. Virus Res. 135:237–246. 2008.

13. Gomaa, M. H., D. Yoo, D. Ojkic, and J. R. Barta. 2009. Infection with a pathogenic turkey coronavirus isolate negatively affects growth performance and intestinal morphology of young turkey poults in Canada. Avian Pathol. 38:279–286. 2009.

14. Guy, J. S. Turkey coronavirus is more closely related to avian infectious bronchitis virus than to mammalian coronaviruses: a review. Avian Pathol. 29:207–212. 2000.

15. Guy, J. S., L. G. Smith, J. J. Breslin, J. P. Vaillancourt, and H. J. Barnes. High mortality and growth depression experimentally produced in young turkeys by dual infection with enteropathogenic Escherichia coli and turkey coronavirus. Avian Dis. 44:105–113. 2000.

16. Ismail, M. M., A. Y. Tang, and Y. M. Saif. Pathogenicity of turkey coronavirus in turkeys and chickens. Avian Dis. 47:515–522. 2003.

17. Maurel, S., D. Toquin, F. X. Briand, M. Queguiner, C. Allee, J. Bertin, L. Ravillion, C. Retaux, V. Turblin, H. Morvan, and N. Eterradossi. First full-length sequences of the S gene of European isolates reveal further diversity among turkey coronaviruses. Avian Pathol. 40:179–189. 2011.

18. Nagaraja, K. V. P., and B. S. Pomeroy. Coronaviral enteritis of turkeys (bluecomb disease). In: Diseases of poultry, 10th ed. B. W. Calnek, H. J. B., C. W. Beard, L. R. McDougald, and Y. M. Saif, eds. Iowa State University Press, Ames, IA. pp. 686–692. 1997.

19. Pantin-Jackwood, M. J., D. M. Smith, J. L. Wasilenko, and E. Spackman. Low pathogenicity avian influenza viruses infect chicken layers by different routes of inoculation. Avian Dis. 56:276–281. 2012.

20. Sawicki, S. G., D. L. Sawicki, and S. G. Siddell. A contemporary view of coronavirus transcription. J. Virol. 81:20–29. 2007.

21. Senne, D. A. Virus propagation in embryonating eggs. In: A laboratory manual for the isolation, identification, and characterization of avian pathogens, 4th ed. D. E. Swayne, J. R. Glisson, J. E. Pearson, W. M. Reed, M. W. Jackwood, and P. Woolcock, eds. American Association of Avian Pathologists, Kennett Square, PA, pp. 235–240. 1998.

22. Thayer, S. G., and C. W. Beard. Serologic procedure. In: A laboratory manual for the isolation, identification, and characterization of avian pathogens, 4th ed. D. E. Swayne, J. R. Glisson, J. E. Pearson, W. M. Reed, M. W. Jackwood, and P. Woolcock, eds. American Association of Avian Pathologists, Kennett Square, PA. pp. 255–266. 1998.

23. Yason, C., and K. A. Schat. Pathogenesis of rotavirus infection in various age groups of chickens and turkeys: clinical signs and virology. Am. J. Vet. Res. 48:977–983. 1987.

24. Yu, M., M. M. Ismail, M. A. Qureshi, R. N. Dearth, H. J. Barnes, and Y. M. Saif. Viral agents associated with poult enteritis and mortality syndrome: the role of a small round virus and a turkey coronavirus. Avian Dis. 44:297–304. 2000.

ACKNOWLEDGMENTS

The authors would like to thank Megan Strother for technical assistance. This study was partially supported by funds appropriated to the Ohio Agricultural Research and Development Center, The Ohio State University.